

# Neural correlates of familiarity and recollection in healthy subjects with *Deja-vu*

Cavalli SM<sup>1</sup>, Passamonti L<sup>2</sup>, Nigro S<sup>2</sup>, Riccelli R<sup>1</sup>, Mumoli L<sup>1</sup>, Borzì G<sup>1</sup>, Chiriaco C<sup>2</sup>, Labate A<sup>1,2</sup>, Gambardella A<sup>1,2</sup>, Quattrone A<sup>1,2</sup>

<sup>1</sup>Institute of Neurology, University "Magna Graecia", Catanzaro, Italy.

<sup>2</sup>Institute of Molecular Bioimaging and Physiology of the National Research Council (IBFM-CNR), Catanzaro, Italy.



**Objectives:** *Deja-vu* (DV) is a transient state of incongruous familiarity feeling about present experience, occurring at least once in life in almost 80% of healthy individuals; it is also reported in patients with mesial temporal lobe epilepsy and psychiatric disorders (e.g., schizophrenia), in which it may represent a key symptom. Past neuroimaging studies, including our own, showed that structural changes in mesio-temporal and extratemporal structures may be associated with an increased tendency to experience DV, although it is unknown whether functional alterations within neural circuits underlying familiarity-based and recollection-based memory may be detected in people with frequent DV episodes. The present study aimed therefore to assess brain functional correlates of familiarity-based and recollection-based memory in healthy subjects with frequent DV episodes compared with healthy individuals without DV.



Fig.1 Example of Encoding (outside the scanner) and Retrieval (inside the scanner) image presentation

**Materials and methods:** To assess the presence of DV, 29 healthy volunteers completed a neuro-psychiatric evaluation, an extensive neuropsychological battery and the Italian version of the Inventory for *Deja-vu* Experiences Assessment (IDEA). Participants also underwent fMRI, performing a specific home-made memory task. It consisted of an Encoding phase (outside the scanner), in which 120 pictures were randomly administered to participants and of a Retrieval phase (inside the scanner, two days later), in which 60 new pictures and the old dataset were displayed together. During the Retrieval, participants had to report whether they felt the pictures weakly familiar, strongly familiar, novel or completely recollected. A factorial model was used to correlate Familiarity and Recollection answers with brain differences between subjects with or without DV. Finally, we also studied which brain areas displayed differential connectivity patterns with the hippocampus as a function of Familiarity and/or Recollection-based memory.

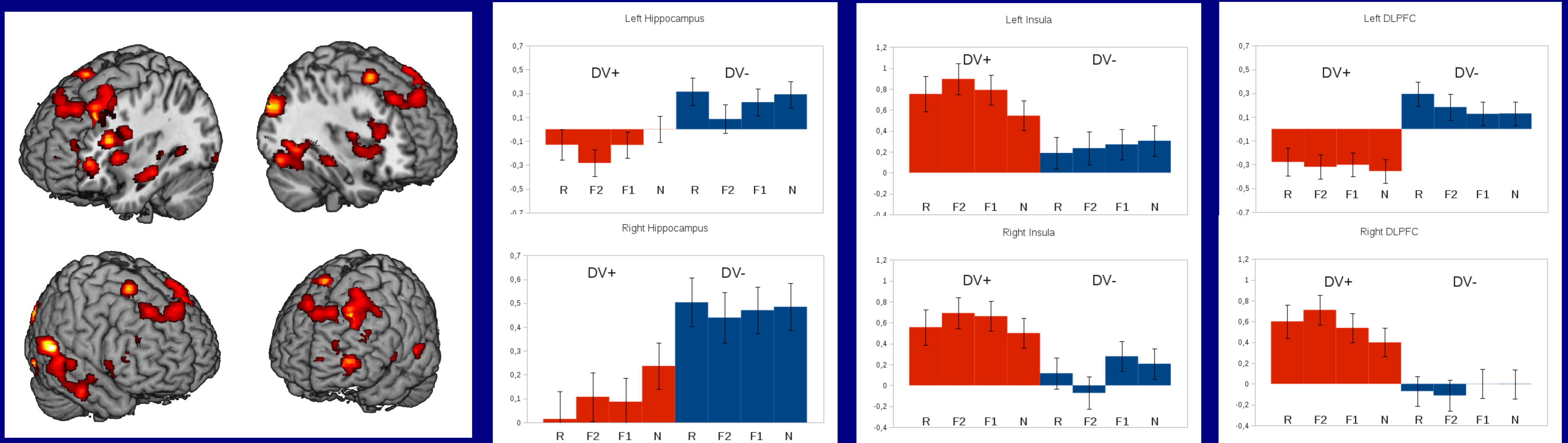


Fig.2 BOLD regional correlates of familiarity and recollection show differences between DV+ and DV- group.

**Results:** Using the IDEA, we identified 15 subjects with (DV+) and 14 without DV (DV-). Compared to DV- individuals, DV+ subjects showed reduced activation, for all task conditions, in the bilateral hippocampus, left thalamus, and left dorsolateral (DLPFC) and ventrolateral prefrontal cortex (VLPFC); conversely, DV+ group showed more activation in right DLPFC and bilateral insula. Finally, they displayed, relative to DV- subjects, increased connectivity changes between left hippocampus and left amygdala, insula, DLPFC, bilateral VLPFC and posterior Cerebellum.

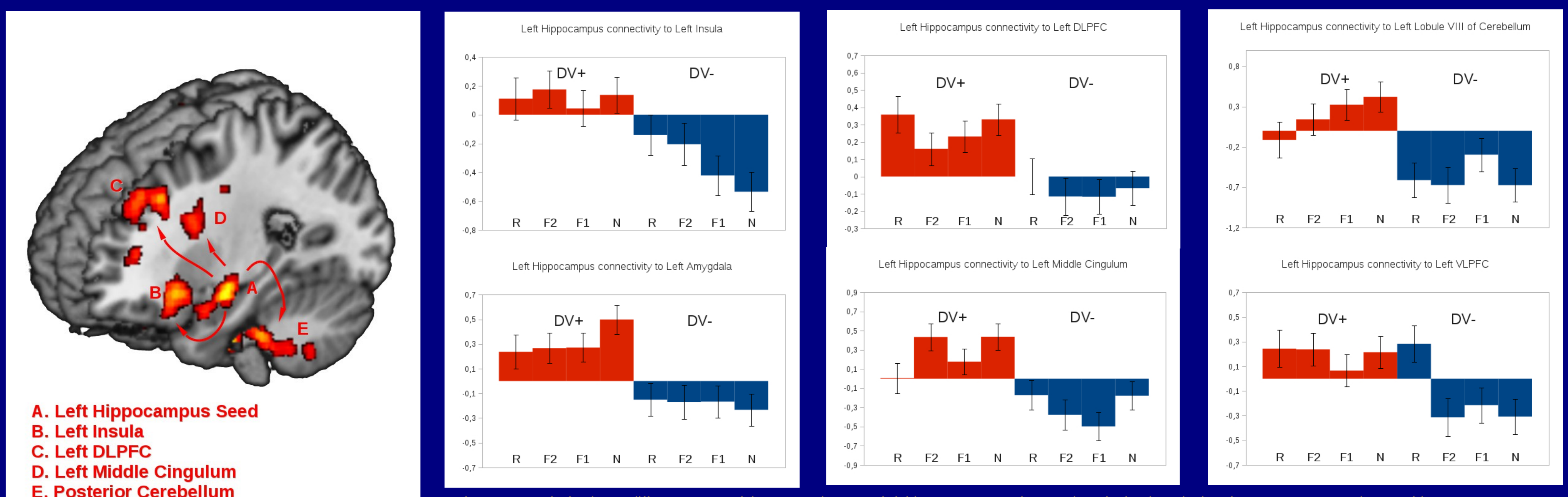


Fig.3: PPI analysis shows different connectivity pattern between left hippocampus and several cortical-subcortical region among DV+ and DV- subjects.

**Discussion and conclusion:** The changes seen in the hippocampus of subjects with DV could represent either an altered function of memory recollection system or in the binding of familiarity-based and recollection-based memory, whereas the increased insular activity could be linked to the high familiarity rates often reported by DV+ subjects.

## References

- Bràzdil M, Mareček R, Urbánek T, Kašpárek T, Miki M, Rektor I, Zeman A, "Unveiling the mystery of *deja vu*: the structural anatomy of *deja vu*", *Cortex*, 2012, 48(9),1240-1243.  
 Labate A, Cerasa A, Mumoli L, Ferlazzo E, Aguglia U, Quattrone A, Gambardella A, "Neuro-anatomical differences among epileptic and non-epileptic *deja vu*", *Cortex*, 2015, 64, 1-7.  
 Montaldi D, Spencer TJ, Roberts N, Mayes AR, "The neural system that mediates familiarity memory", *Hippocampus*, 2006, 16(5), 504-20.