



# The novel *GRN* g.1642\_1645delTGAG mutation is associated with language and behavioural impairment, and parkinsonism.



S.M.G. Cioffi <sup>1</sup>, A Espay <sup>2</sup>, C Fenoglio <sup>1</sup>, M Serpente <sup>1</sup>, M Arcaro <sup>1</sup>, E Oldoni <sup>1</sup>, R Ardizzoia <sup>1</sup>, MC Hagen <sup>2</sup>,

F Rodriguez-Porcel <sup>2</sup>, E Scarpini <sup>1</sup>, D Galimberti <sup>1</sup>

<sup>1</sup> University of Milan, Fondazione Ca' Granda, IRCCS Ospedale Policlinico, Milan, Italy

<sup>2</sup> Gardner Family Center for Parkinson's Disease and Movement Disorders, Department of Neurology, University of Cincinnati, Cincinnati, Ohio, USA

## BACKGROUND

❖ Mutations in Progranulin gene (*GRN*) are a common cause of autosomal dominant Frontotemporal Lobar Degeneration (FTLD). The clinical presentation in *GRN* mutation carriers is extremely heterogeneous in terms of symptoms, disease duration and age of onset.

❖ The majority of genetic defects in *GRN* are loss-of-function mutations, causing plasmatic haploinsufficiency and are associated with extremely heterogeneous clinical presentation [1] and TAR DNA binding protein (TDP-43) pathology [2].

❖ Point mutations and variants affecting the splicing have been described [3]. The penetrance of *GRN* mutations is incomplete and this condition is probably due to the presence of other genes influencing the manifestation of the disease.

## MATERIALS & METHODS

❖ **Subjects:** medical history, screening laboratory tests, neurocognitive evaluation and imaging were in accordance with Raskovski criteria diagnosis [4].

❖ **Progranulin plasma levels evaluation:** through an ELISA kit (Adipogene, Korea).

❖ **DNA isolation and genotyping:** by Flexigene Kit (Qiagen, Germany); *GRN* screening was performed by AB3130 automated sequencer (Applied Biosystem).

❖ **Brain RNA Extraction:** by Direct-zol RNA miniPrep spin column purification (ZYMO Research).

❖ **cDNA PCR analysis:** a gradient PCR was performed to evaluate the *GRN* portion between the exon 5 and exon 8 and *GAPDH* housekeeping gene.

❖ **RT-PCR analysis:** RNA was reverse-transcribed (SuperScript III First-Strand Synthesis System SuperMix, Thermo Fischer Scientific); the amount of mRNA levels of *GRN* in the brain was determined by comparison with three housekeeping genes (*18S*, *GAPDH*,  $\beta$ -*actin*). Different control brain tissues obtained by human donor patient (Biochain®) were used.

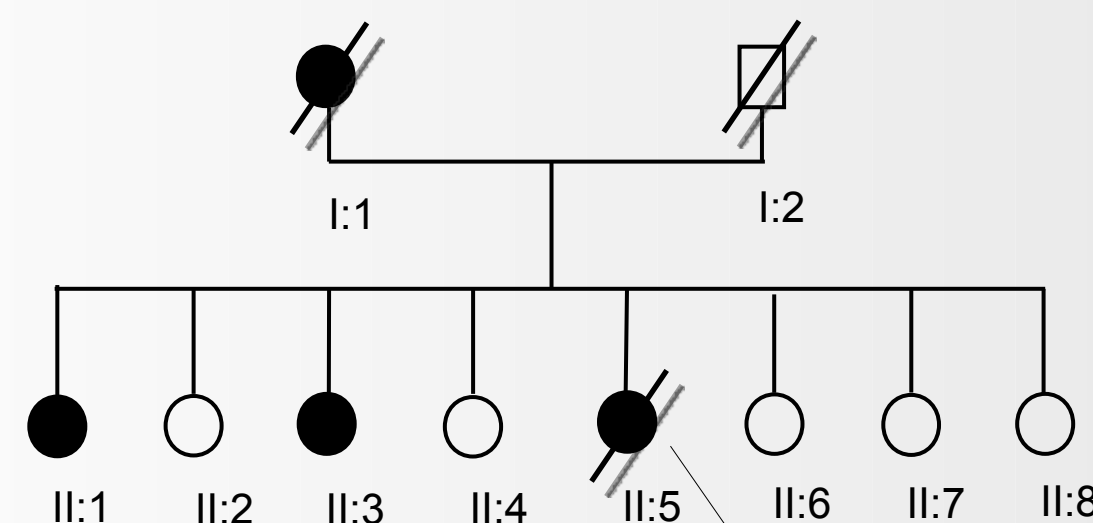
❖ **In silico analysis:** Spliceport website (<http://spliceport.cbcb.umd.edu/>); Ensembl Genome Browser (<http://www.ensembl.org/index.html>).

## AIM

Here we describe the clinical, pathological, and genetic abnormalities of a patient with Primary Progressive Aphasia non-fluent variant (PNFA), and study the segregation of a novel *GRN* mutation localized in a putative splicing consensus sequence.

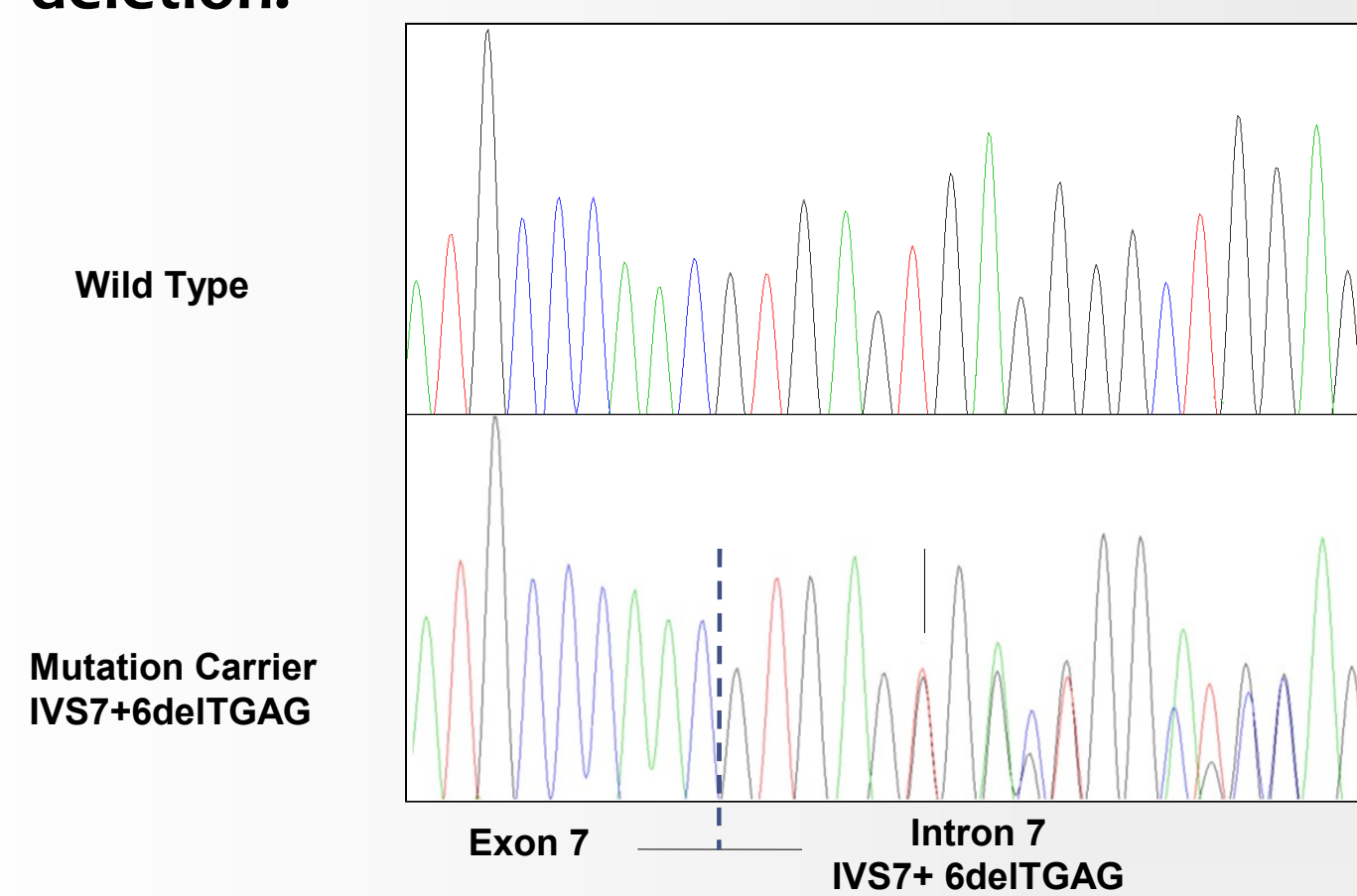
## CLINICAL HISTORY

A 66-year-old-woman (II:5) developed progressive aphasia, behavioural changes and parkinsonism with rigidity, bradykinesia, resting tremor and impaired postural reflexes. The deterioration of her language accelerated after a year, limiting her verbal repertoire. Her family history was positive for dementia in her mother (I:1) and two sisters (II:1, II:3). Brain MRI showed atrophy in the frontal and anterior temporal lobes. Her clinical course continued to deteriorate to an akinetic mutism, bed-bound state. She died four years from disease onset, at the age of 68 years.



## MOLECULAR GENETIC ANALYSIS

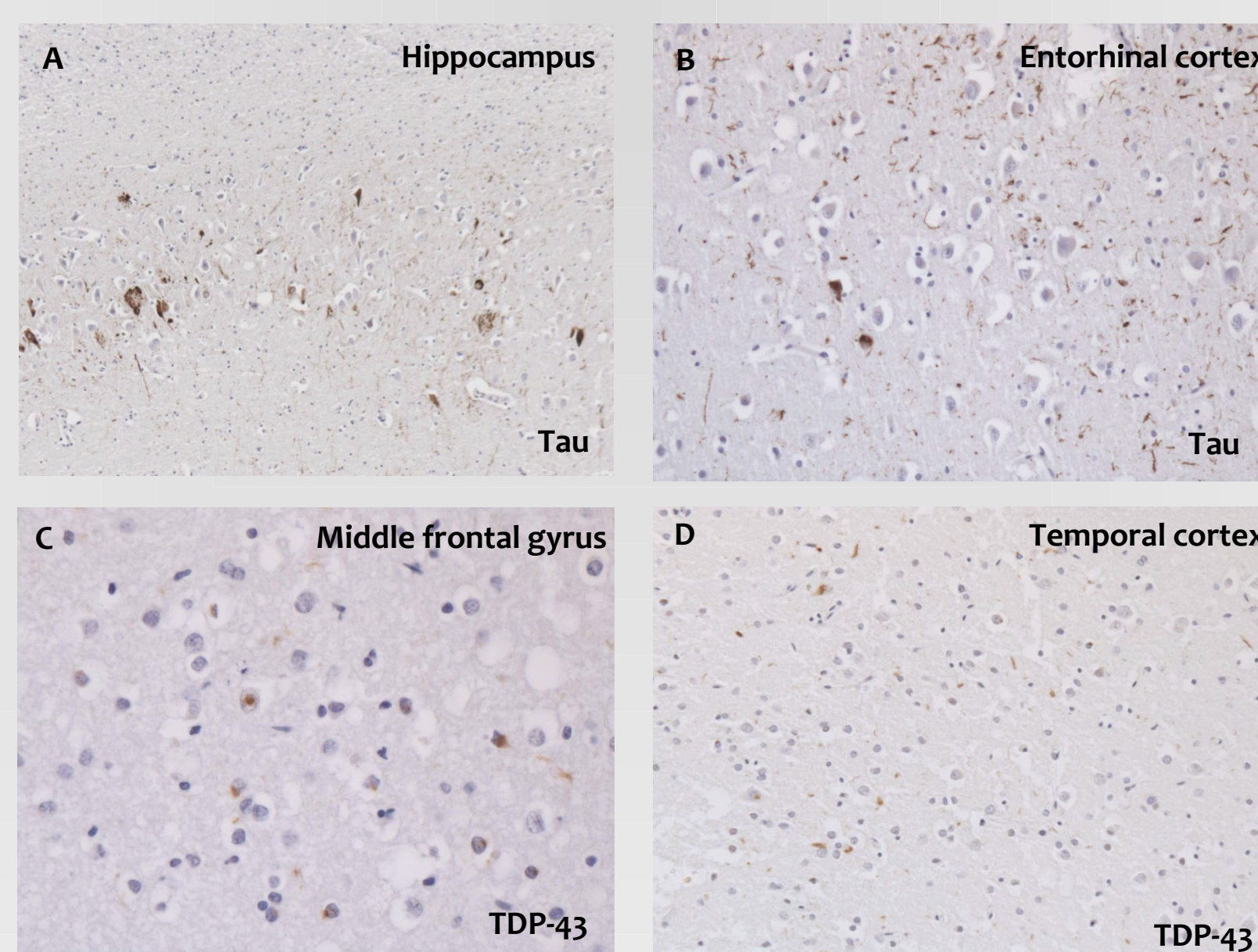
Plasma progranulin levels were 27 ng/mL (cut-off 61 ng/mL). By direct sequencing a novel deletion (g.1642\_1645TGAG) in the 3' flanking region of exon 7 was found (IVS7+6delTGAG). In silico analysis predicted that the wild type sequence is localized in a possible donor splice site, which is abolished by the deletion.



## RESULTS

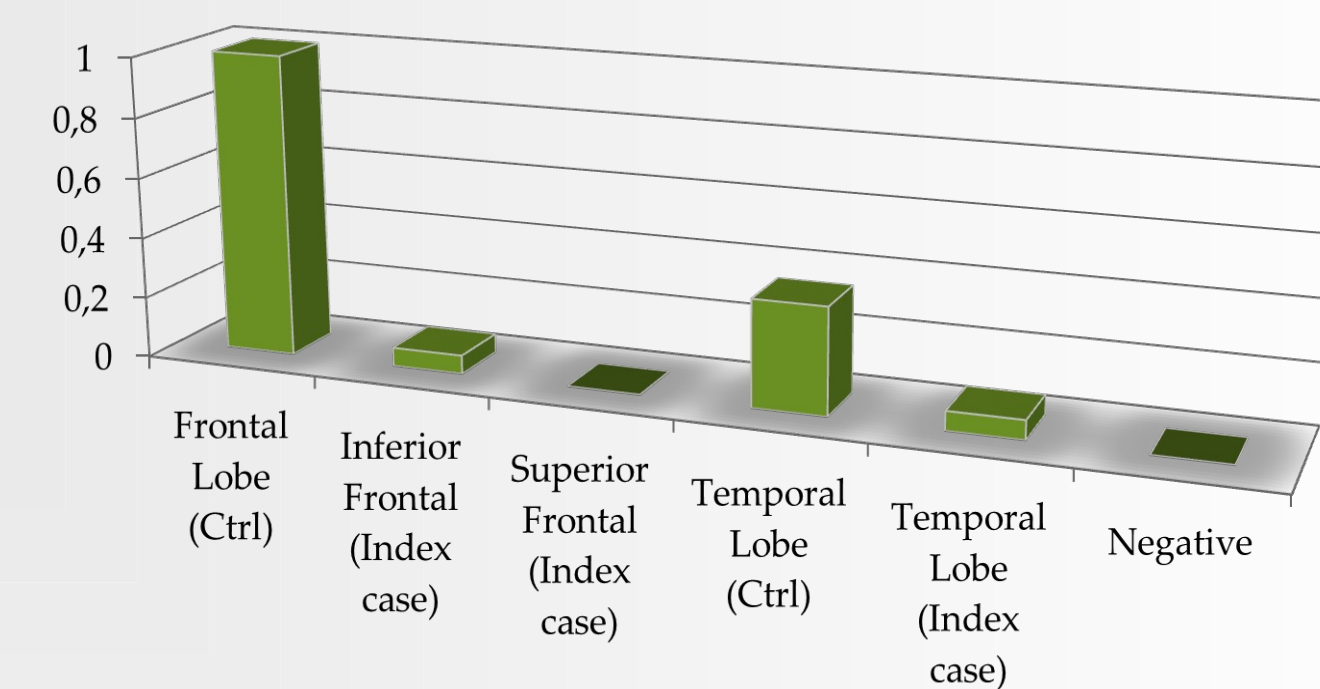
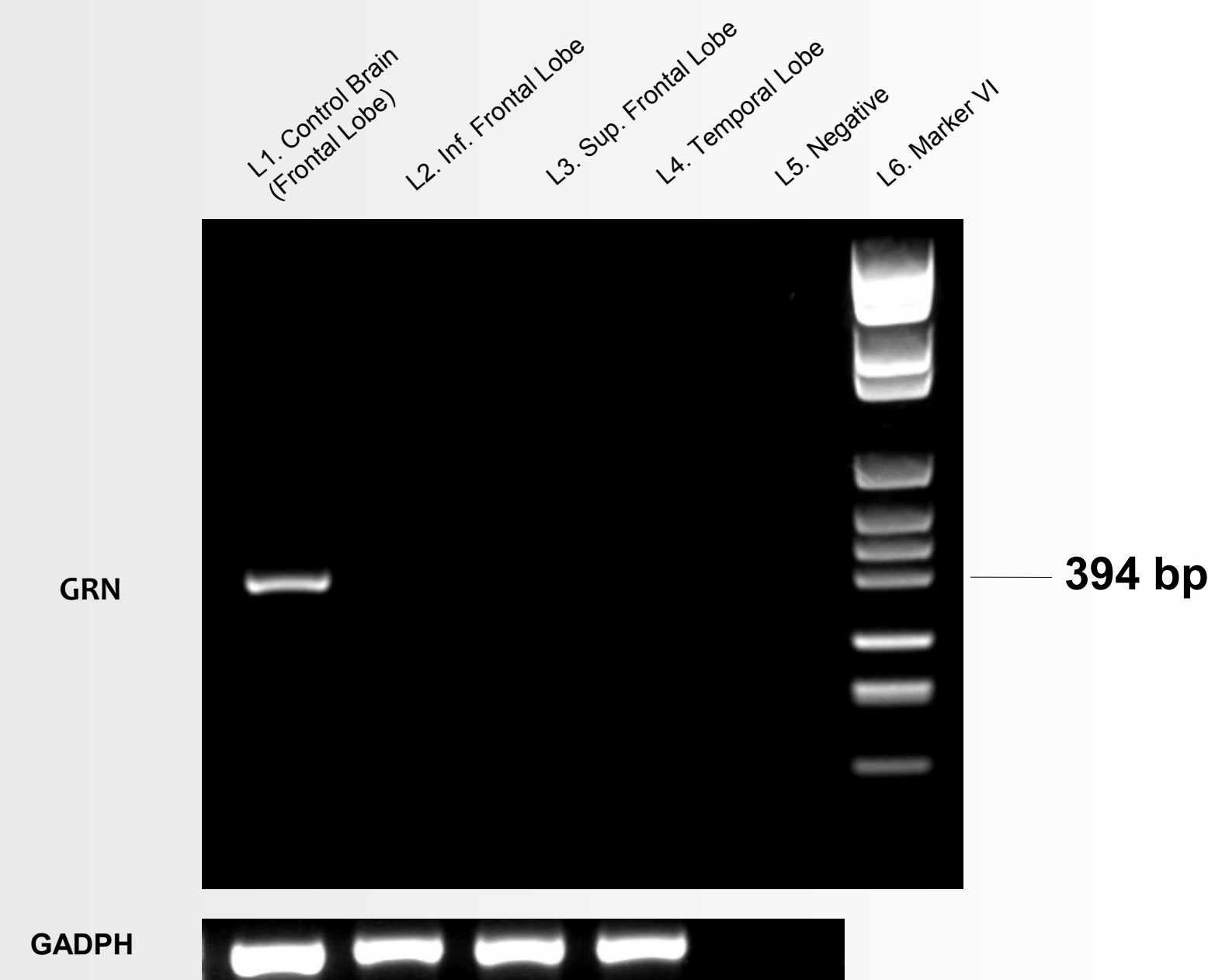
### AUTOPSY FINDINGS

The fresh brain showed severe atrophy of the frontal and temporal lobes. Histologically, there was severe neuronal loss and gliosis in neocortex, caudate nucleus, putamen, globus pallidus, hippocampus, dentate nucleus, substantia nigra, inferior olivary nucleus. Rare neurofibrillary tangles and tau-immunoreactive neurons were found in putamen, hippocampus (A), and entorhinal cortex (B). TDP-43-immunoreactive neuronal cytoplasmic and, occasionally, intranuclear inclusions as well as dystrophic neurites were detected in frontal (C), parietal and temporal cortices (D), cingulate gyrus, precuneus, thalamus, subthalamic nucleus, hippocampus and entorhinal cortex.



### GRN EXPRESSION ANALYSIS

Semi-quantitative expression analysis was carried out by PCR in inferior and superior frontal cortex as well as in temporal lobe, showing that *GRN* is not expressed in the brain of the patient. Quantitative RT-PCR was carried out, confirming that *GRN* was not expressed in the superior frontal cortex, whereas its expression was strongly reduced in inferior frontal cortex and reduced in temporal lobe.



## DISCUSSION

❖ We described the clinical phenotype and pathology of a patient with rapidly progressive FTD expressed as PNFA and parkinsonism associated with the novel *GRN* mutation IVS7+6delTGAG;

❖ the variant segregates with the disease in the index case and in two other family members with dementia and the pathology demonstrates TDP-43 accumulation;

❖ the deletion is localized in a highly conserved region and is predicted to abolish a splicing consensus sequence;

❖ we showed that the expression of the gene is strongly reduced, or even absent, in frontal and temporal cortex.

## REFERENCES

1. Cerami C, Scarpini E et al., (2012) Frontotemporal lobar degeneration: current knowledge and future challenges. *J. Neurol.* 259(11), 2278-2286.
2. Neumann M, Sampathu DM, et al., (2006) Ubiquitinated TDP-43 in frontotemporal lobar degeneration and amyotrophic lateral sclerosis. *Science* 314(5796), 130-133.
3. Leverenz JB, Yu CE, et al., (2007) A novel progranulin mutation associated with variable clinical presentation and tau, TDP43 and alpha-synuclein pathology. *Brain* 2007;130(Pt 5):1360-74.
4. Rascovsky K, Hodges JR, et al., (2011) Sensitivity of revised diagnostic criteria for the behavioural variant of frontotemporal dementia. *Brain* 134(Pt 9), 2456-77.

Contact: [sara.cioffi@unimi.it](mailto:sara.cioffi@unimi.it)