

NUMMULAR HEADACHE ATTRIBUTED TO LANGERHANS CELLS HISTIOCYTOSIS. EVIDENCE OF A PERIPHERAL MECHANISM?

B. Colombo, G. Magnani, C. Mandelli, M. Terreni, P. Vezzulli, G. Comi

Università Vita-Salute San Raffaele - Istituto Scientifico Ospedale San Raffaele - Milano

Introduction:

Nummular headache is a rare disorder defined as an oppressive, continuous or intermittent pain felt exclusively in a rounded area of the head, typically 1 cm to 6 cm in diameter. It is classified (ICHD-III beta) under the category of "other primary headaches". Yet, a very few secondary cases have been communicated. We describe a symptomatic case as an evidence for a peripheral mechanism of this circumscribed head pain.

Methods:

Observational case report.

Results:

A 29-year-old female was referred to our headache centre due to a two months history of focal pain located in a circular area, with the diameter of about 4 cm, on the right parietal region. She described it as a mild, continuous pressure-like pain. The pain was not responsive to NSAIDs. Local inspection was normal, but careful palpation revealed a focal painful tender area, exacerbated or triggered by touch (VAS 8) on the right parietal area referred as the site of circumscribed pain. CT scan and MRI (**Figure 1**) revealed a small intradiploic lesion, with gadolinium enhancement, T1 isointensity with tissues and T2-FLAIR hyperintensity, corresponding to the area of pain localization. Patient was referred to neurosurgery department and the symptomatic area was eventually removed. After surgery, the head pain completely disappear. The histologic diagnosis (**Figure 2**) was in accordance to a Langerhans cells histiocytosis (immunoreaction for protein S-100 and CD1a). The diagnostic workout (Total body CT scan, PET 18-f FDG) was negative for other localizations of the disease. Clinical follow-up (after 3-6-12 and 18 months) confirmed the complete resolution of pain.

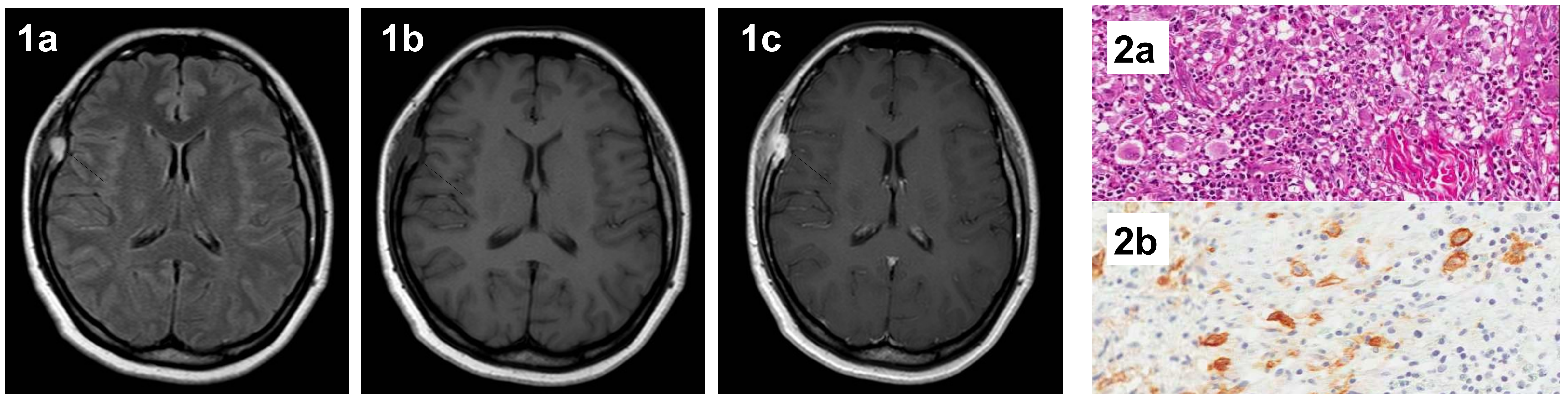


Figure 1. MRI showing a small intradiploic lesion of the skull in the right frontotemporal region with initial subgaleal soft tissue involvement (red arrow). Signal analysis of the lesion revealed FLAIR hyperintensity (1a) and T1 isointensity (1b) with important contrast enhancement after gadolinium infusion (1c).

Figure 2. HE staining showing mixed infiltrate of lymphocytes, plasma cells, eosinophils and histiocytes (2a). CD1a positivity typical of Langerhans cells (2b)

Conclusions:

Although nummular headache is classified as a primary disorder, our case (headache with a clear nummular pattern) was related to a focal lesion of the skull. Complete resolution of symptomatology after surgical treatment fortify the presumption of a secondary case. The clinical history of our case supports the peripheral origin of nummular headache: when the symptomatic area was removed, the headache ceased, with no recurrence. The periosteum is the pain-sensitive structure of the diploe. In our case, nummular headache might be interpreted as a local pain disorder stemming from terminal branches of sensory nerves. Furthermore, this is the first case attributed to a localized Langerhans cells histiocytosis. Although only few cases were described, we suggested a revision of ICHD-III criteria, including symptomatic nummular headache as a secondary headache attributed to underlying structural lesions.