



# Migraine with aura post IMA and coronary stenting may be a model of microembolism that triggers cortical spreading depression

Virginia Annese, Veronica Boccioletti, Sara Lombardi, Roberta Fasolo, Simone Fusina

Division of Neurology - Hospital S. Bonifacio - Verona, Department of Medicine - Hospital S. Bonifacio - Verona

**Introduction:** Previous research shows that air microembolism through large PFOs may cause cerebral bioelectrical disturbances and, occasionally, headache in MA patients. This may reflect an increased reactivity of their brain to transient subclinical hypoxia-ischemia (1). Similarly, cerebral embolism during PFO closure led to migraine attacks shortly after the intervention (2).

At a follow-up of 12 months PRIMA trial has showed a significant reduction of migraine with aura (days) in patients treated with PFO closure compared to the medical therapy group.

Vigna observed improvement of moderate/severe migraine after PFO (with large RLS) percutaneous closure in patients with subclinical brain lesions (a case-control study)(4). Wahl highlighted an improvement of migraine headaches, especially MA, after percutaneous closure of PFO for secondary prevention of paradoxical embolism (5).

The presence of prothrombotic hematologic factors or conditions that are increasing intrathoracic pressure may predispose these patients to cerebral microembolism, similar to stroke in patients with paradoxical embolism (6). Indeed, there are several lines of evidence to suggest that cerebral microembolism can potentially trigger cortical spreading depressions (CSDs), possibly by causing small brain foci of hypoxia-ischemia (7,8)

**Case presentation:** We describe a 74 years old woman who presented the first episode of migraine with aura after myocardial infarction and coronary stent. At a young age she suffered from migraine without aura.

PRA: hypertension; type 2 diabetes; dyslipidemia; smoking; slight IRC.

PPA: In November 2013 the patient had an heart attack and underwent angioplasty with stent on December 5th. Since December 23rd she has reported the appearance of about 10 episodes characterized by feeling weakened right arm, followed by numbness tingling in kind, migrants, the same venue (on one occasion with the extension to the neck and jaw right) and lastly feeling of blurring of vision on the right with fortified appearance, awkward in speech lasting 15-30 minutes. These symptoms were sometimes followed by throbbing headache, frontotemporal, with intensity until 8VAS, associated with nausea / vomiting, photo-phono-osmophobia, lasting 6-12 hours. She reported an episode of blurred vision with fortified appearance, lasting a few hours, during a coronary angiography 10 years before. At home she was treated with clopidogrel 75 mg / day, ASA 100 mg / day, bisoprolol, ramipril, canrenone, metformin.

MRI brain with contrast medium (January 16, 2014): In the sequences with long TR (T2 / DP, FLAIR) signs of leukoaraiosis. DWI sequences in multiple cortical hyperintense foci minutes to left (frontal and occipital region) and the head of the caudate nucleus ipsilateral (ischemic lesions recent). MR angiography study (TOF sequences), there were no vascular malformations, no stenosis-occlusions of the main branches of the circle of Willis Intracranial; threadlike the posterior communicating arteries

Echocardiogram TE: dilatated right ventricle, with wide area of inferior-posterior and apical akinesia and overall efficiency reduced so average-severe.

EcoDoppler TSA: hyperechoic plaque, with smooth surface at the right ICA (stenosis 40%) and ICA sin (28% stenosis)

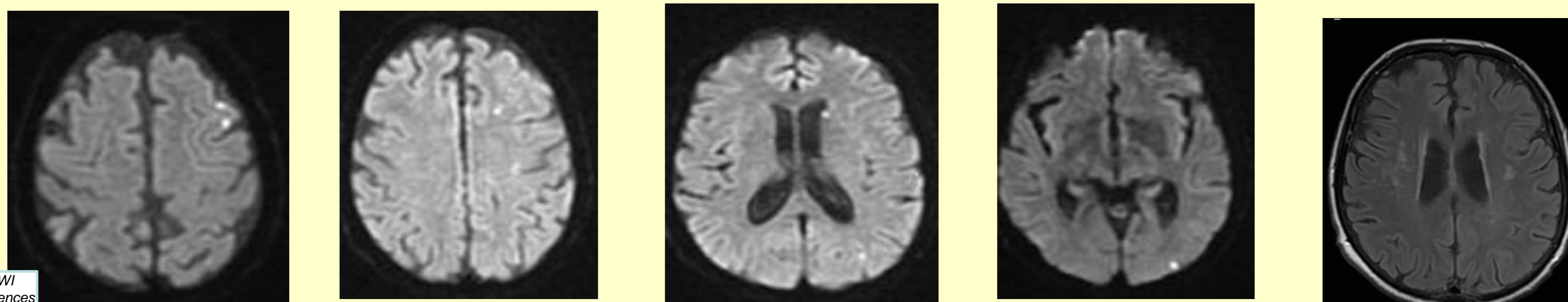
TSH normal, homocysteine 16.3 mic / dl.

It started during hospitalization prophylaxis with warfarin in combination with clopidogrel 75 mg/day, folina 5 mg/day and atorvastatin 80 mg/day. It ended for ischemic lesions of probable cardio-embolic in recent heart attack

At control visit of January 16, 2014 she reported the persistence of episodes of paresthesias cheiro right-oral, lasting 5-15 minutes, sometimes followed by migraine-type headache (1-2 episodes per month)

Neurologic examination it showed only a slight deficit stenico right brachial residue with ROT lively upper limbs dx > sin

At control visit of April 2014 she had suspended the clopidogrel and reduced the atorvastatin 40 mg / day. They persisted episodes of paresthesias cheiro right-oral, lasting 5-15 minutes, sometimes followed by migraine-type headache (1-2 episodes per month). No new lesions on MRI brain control



**Conclusion:** it is possible to observe that MA patients' brain is sensitive to embolism-induced perturbations. Supporting this idea, studies in mice report that the bioelectrical disturbances are correlated with the intensity of microembolism-induced hypoperfusion. Several studies have suggested that interictal cortical excitability is increased in migraineurs. Genetic susceptibility and environmental factors may cause the extracellular K<sup>+</sup> and glutamate levels to sufficiently rise and initiate CSD or a CSD-like depolarizing event. Microembolism can potentially trigger abnormal bioelectrical activities that may be followed by MA whether the patient is susceptible (6,7,8) Subclinical hypoxia-ischemia induced by paradoxical cerebral embolism is not a common cause of migraine attacks in MA patients but may occasionally trigger aura and migraine with aura in the susceptible brain

**References:** 1. Paradoxical Air Microembolism Induces Cerebral Bioelectrical Abnormalities and Occasionally Headache in Patent Foramen Ovale Patients With Migraine Eser Basak Sevgi, Sefik Evren Erdener, Mehmet Demirci, Mehmet Akif Topcuoglu, Turgay Dalkara, PhD *J Am Heart Assoc.* 2012 Dec;1(6):e001735.  
2. Rigatelli G, Cardaioli P, Dell'Avvocata F, Giordan M, Braggion G, Chinaglia M, Roncon L. Transcatheter patent foramen ovale closure is effective in reducing migraine independently from specific interatrial septum anatomy and closure devices design. *Cardiovasc Revasc Med.* 2010;11:29-33  
3. David Hildick-Smith PFO Closure Fails Anew in Migraine: PRIMA. *Medscape.* Sep 16, 2014  
4. Vigna C, Marchese N, Inchingolo V, Giannatempo GM, Pacilli MA, Di Viesti P, Impagliatelli M, Natali R, Russo A, Fanelli R, Loperfido F. Improvement of migraine after patent foramen ovale percutaneous closure in patients with subclinical brain lesions: a case-control study. *JACC Cardiovasc Interv.* 2009;2:107-113.  
5. Wahl A, Praz F, Tai T, Findling O, Walpoth N, Nedeltchev K, Scherzmann M, Windecker S, Mattle HP, Meier B. Improvement of migraine headaches after percutaneous closure of patent foramen ovale for secondary prevention of paradoxical embolism. *Heart.* 2010;96:967-973  
6. Rigatelli G. Migraine and patent foramen ovale: connecting flight or one-way ticket?. *Expert Rev Neurother.* 2008;8:1331-1337  
7. Nozari A, Dilekoz E, Sukhotinsky I, Stein T, Eikermann-Haerter K, Liu C, Wang Y, Frosch MP, Waeber C, Ayata C, Moskowitz MA. Microemboli may link spreading depression, migraine aura, and patent foramen ovale. *Ann Neurol.* 2010;67:221-229  
8. Dalkara T, Zervas NT, Moskowitz MA. From spreading depression to the trigeminovascular system. *Neurol Sci.* 2006;27suppl 2S86-S90