

Post-stroke neglect and cranioplasty: a case report

F. Corallo, V. Lo Buono, C. Smorto, D. Galletta, A. Marra, P. Bramanti, R.S. Calabro'

¹IRCCS Centro Neurolesi "Bonino-Pulejo", Messina, Italy

Objective:

Patients with neglect have difficulty in detecting and identifying objects, and executing movements in the portion of space contralateral to the lesion side, even though they are not blind to stimuli on that side. Neglect is a relatively frequent consequence of acute stroke (with a 25-30% incidence), quite often having a spontaneous resolution. However, when it is persistent, no treatment has yet demonstrated a long term efficacy. Indeed, the conventional rehabilitation of neglect, including visual scanning and limb activation training or optokinetic stimulation, have produced varying degrees of improvement, lasting from several minutes up to several months after training (1-2). The aim of the study was to assess the short-term effects on the recovery of the cranioplasty neglect.

Materials and Methods:

An otherwise healthy 44-year-old male was admitted to a Neurosurgical ward since affected by consciousness impairment and right hemiplegia due to intracerebral hemorrhage following right middle cerebral artery bifurcation aneurysm rupture. A right fronto-tempo-parietal craniotomy, with prompt removal of the hematoma and simultaneous clipping of the aneurysm, was urgently performed. After around a month from the stroke onset, he was admitted to our Research Institute for an intensive neurological rehabilitation (consisting of motor and cognitive training performed twice/daily), with a progressive improvement in general and neurological conditions. Only neglect symptoms and anosognosia persisted nearly unchanged, despite the fact that the patient performed a specific neglect training.

Results and Discussion:

The Behavioural Inattention test (score T0:14; T1:14; T2:5), and Visuo-Analogue Test For Anosognosia For Motor Impairment (score T0: 90; T1: 88; T2:140), supported our noteworthy Findings (Fig. 1). Notably, at one year follow-up the patient showed only a moderate hemiparesis with mild spasticity. Neglect instead dramatically disappeared after cranioplasty. Although several studies have shown the potential improvement of neuropsychological function after cranioplasty (maybe thanks to cerebral blood flow restoration), to date the relationship between neglect and cranioplasty had never been reported.

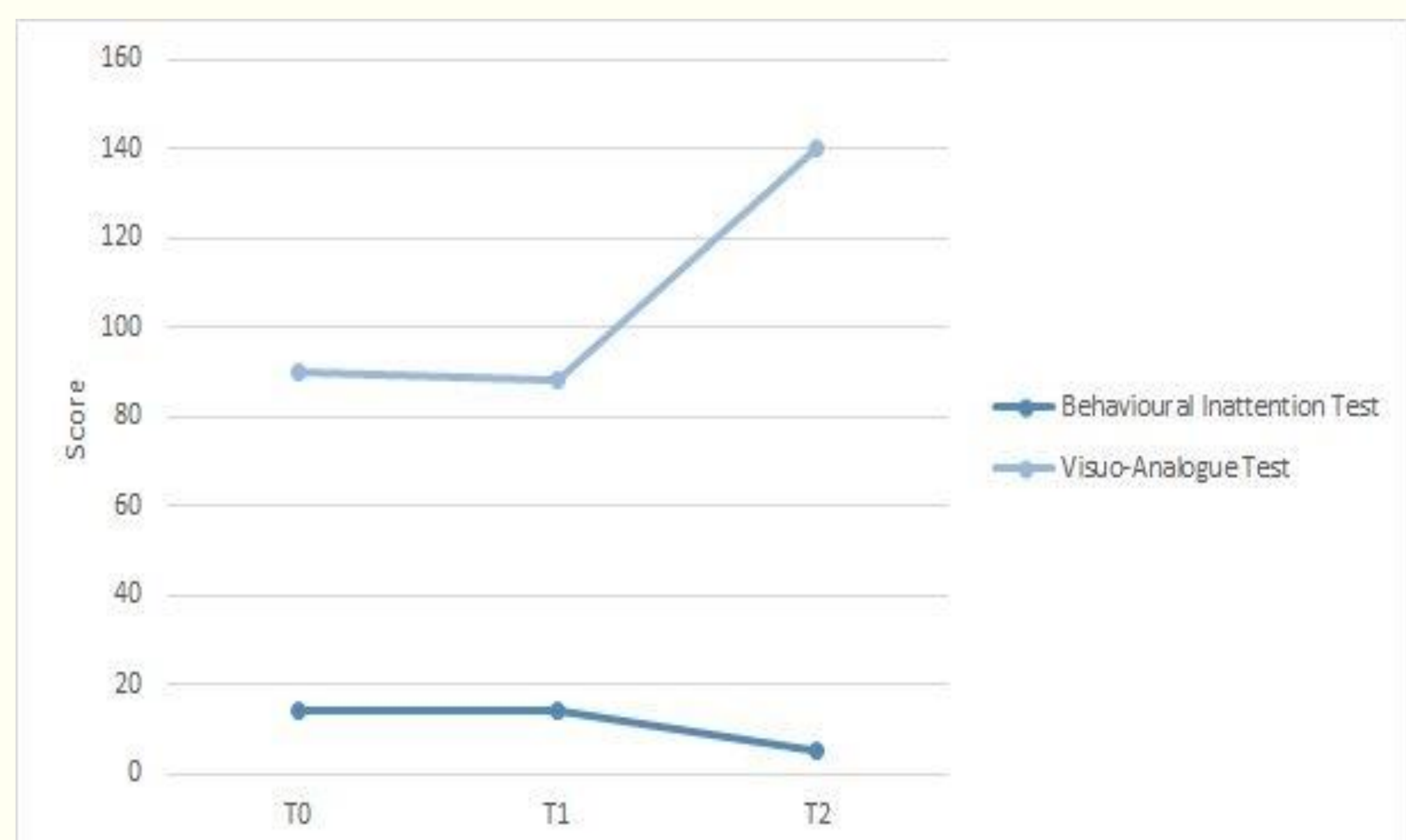


Fig. 1:

Graphical representation of the scores obtained from the clinical scales and neuropsychological assessment

Conclusion

This case demonstrates a strong evidence of a possible recovery of visuospatial attention and anosognosia after cranioplasty. Indeed, although a concomitant effect of the intensive neurorehabilitation may not be completely ruled out, the pivotal role of cranioplasty was demonstrated by the dramatic neglect remediation immediately after such neurosurgical procedure. The repair of cranial defect seems to offer clear benefits in terms of improvement either in motor or in cognitive function, including visuospatial attention.

References

1. Corallo F, Marra A, Bramanti P, Calabro' RS. Effect of cranioplasty on functional and neuro - psychological recovery after severe acquired brain injury: fact or fake? Considerations on a single case. *Funct Neurol.* 2014; 16:1-3.
2. Corbetta, M, Shulman GL. Spatial neglect and attention networks. *Annu Rev Neurosci.* 2011;34:569-99