

Hemorrhagic transformation in ischemic stroke treated with intravenous thrombolytic treatment.

E. D'Errico, M. V. Rossi, E. Caputo, V. Lucchese, M. Gatto, G. Manobianca and F. Tamma

Neurological Department, General Regional Hospital "F. Miulli" - Acquaviva delle Fonti (BA)

Background:

Systemic thrombolysis with intravenous Alteplase (0,9 mg/kg) for acute ischemic stroke significantly improves functional outcome and health-related quality of life, despite an increased risk of fatal intracranial hemorrhage during the first few days.

The earlier the treatment, the larger the clinical benefit.

Recent revisions of guidelines no longer take into account age of the patient and severity of stroke.

Case Report:

a 93 years-old man was led to the emergency room, because of the sudden onset 2 hours before of *right hemiparesis and aphasia*.

Clinical history: previous ischemic stroke (25 years before), diabetes mellitus, hypertensive cardiopathy and chronic atrial fibrillation (treated with warfarin and cardioaspirin).

He didn't show cognitive impairment and was independent in performing common activities of daily living (Rankin scale 1).

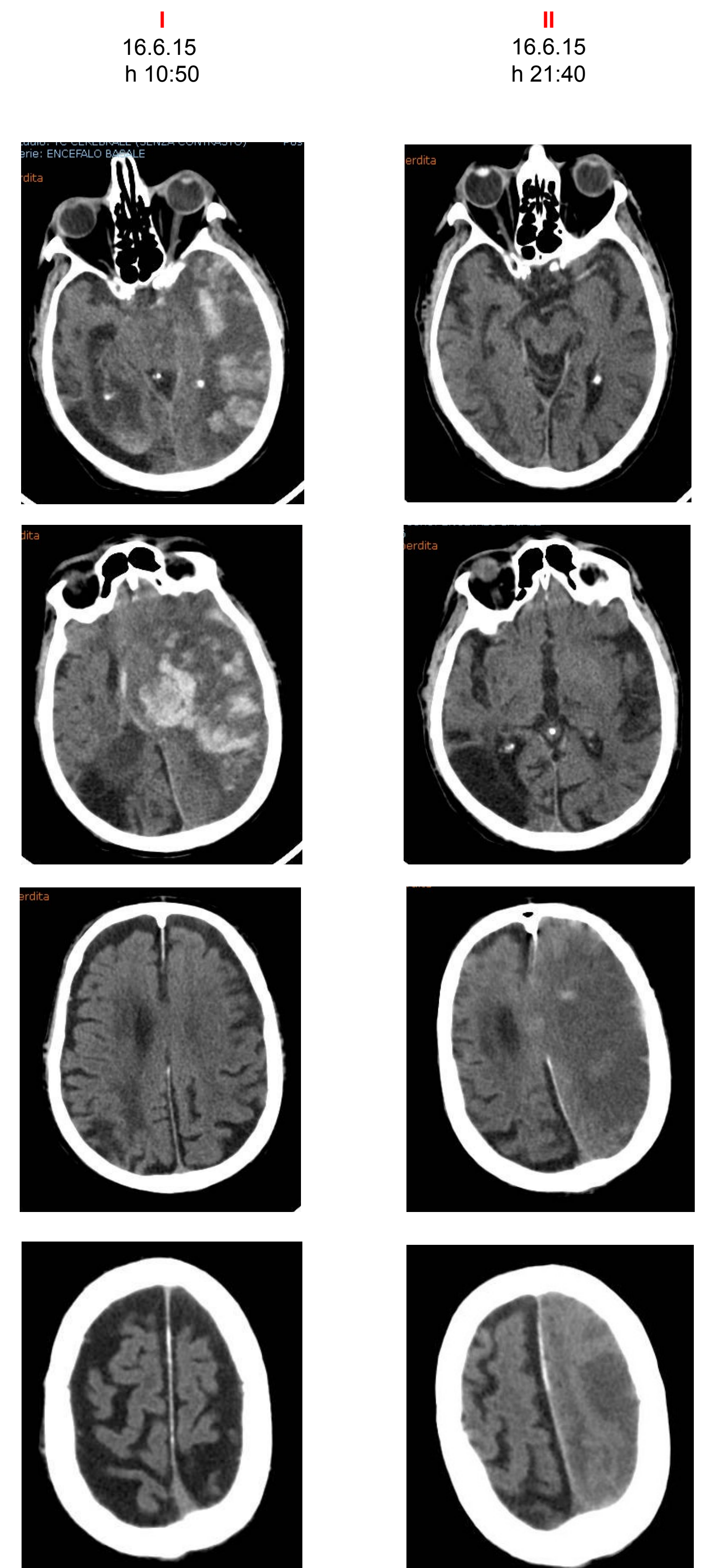
Neurological examination: right hemiplegia and hemianaesthesia, right hemianopia, complete global aphasia (NIHSS score 25).

CT scan detected only left middle cerebral artery hyperdensity. Laboratory tests showed an INR value of 1.53.

We discussed the clinical scenario with his relatives: all inclusion criteria for venous thrombolysis were satisfied and contraindications excluded.

3.5 hours after symptom onset venous thrombolysis was started (Alteplase 0,9 mg/kg). The neurological status remained stable along the first 10 hours, and then worsened suddenly, turning into a deep comatose status with anisocoria and ataxic breathing; NIHSS score was 40 and the GCS 3. Brain CT scan detected extensive left fronto-temporo-parietal hemorrhage, in the context of wide left hemispheric ischemic area.

The patient died after a few hours.



Discussions and Conclusions

According to the recent revision of treatment guidelines on venous thrombolysis treatment, our patient presented no contraindication for the intended procedure.

However coexisted several features which in the recent past contraindicated the treatment: **older than 80yrs age**, **clinical severity (NIHSSs 25)**, ongoing **therapy with anticoagulants** (although the PT INR was less than 1.7) **and cardio aspirin**, and **association of previous ischemic stroke with diabetes mellitus**; moreover **cardioembolic** nature of stroke is associated with a greater haemorrhagic risk transformation.

In light of our experience we wonder whether it is more just **to maintain a more cautious approach in starting thrombolytic treatment in elderly patients, when more than one relative contraindications to thrombolysis coexist, even if all inclusion and exclusion criteria are satisfied.**

References:

- 1) IST-3 collaborative group. Effect of thrombolysis with alteplase within 6 h of acute ischaemic stroke on long-term outcomes (the third International Stroke Trial [IST-3]): 18-month follow-up of a randomised controlled trial. *Lancet Neurol.* 2013 Aug;12(8):768-76.
- 2) Emberson J, Lees KR, et al. Effect of treatment delay, age, and stroke severity on the effects of intravenous thrombolysis with alteplase for acute ischaemic stroke: a meta-analysis of individual patient data from randomised trials. *Lancet.* 2014 Nov 29;384(9958):1929-35.
- 3) Seet RC, Rabinstein AA. Symptomatic intracranial hemorrhage following intravenous thrombolysis for acute ischemic stroke: a critical review of case definitions. *Cerebrovasc Dis.* 2012;34(2):106-14.