



SUBACUTE ONSET OF GM1-GM2 IgM-POSITIVE, MULTICRANIAL AND AUTONOMIC NEUROPATHY IN A PATIENT WITH TYPE 2 DIABETES MELLITUS

Garnero M¹, Schirinzi E², Beronio A², Grandis M¹, Schenone A¹, Mancardi GL¹, Benedetti L^{1,2}

¹ Department of Neuroscience, Rehabilitation, Ophthalmology, Genetics, Maternal and Child Health (DINO-GMI), University of Genoa

² Department of Neurology, S. Andrea Hospital, La Spezia



Background

Autoimmune neuropathies, such as chronic inflammatory demyelinating polyneuropathy and diabetic amyotrophy, can overlap to diabetic neuropathy (ref. 1-2). We describe an atypical, multicranial, autonomic, GM1-GM2 IgM-positive neuropathy with subacute onset, chronic course and improvement after high dosage of corticosteroid therapy.

Case description

CLINICAL HISTORY

A 69-year-old man with Type 2 Diabetes Mellitus (T2-DM) presented with a two-month history of progressive numbness and tingling in both lower limbs, diplopia, hiccup, dysphagia, nausea, and difficulty to digest resulting in lack of appetite (weight loss of 10 Kg). He underwent to neurological examination, brain MRI, ENG study, blood tests and lumbar puncture.

NEUROLOGICAL EXAMINATION

The patient showed right VI and bilateral VII cranial nerve deficits; normal sensory and motor systems at the four limbs; normal deep tendon reflexes. During the hospitalization, he developed orthostatic hypotension, tachycardia, hyperhidrosis and profuse salivation.

Results- Laboratory tests

SERUM:

ANA, ENA, serum immunoelectrophoresis, cryoglobulins, anti-HCV antibodies, ganglionic acetylcholine receptor antibodies, anti-GQ1b antibodies, neoplastic and paraneoplastic markers → negative/normal
GM1-GM2 IgM → positive

CSF:

slightly elevated proteins,
no pleocytosis,
presence of oligoclonal IgG bands (OCBs), equally in serum and CSF (mirror pattern)

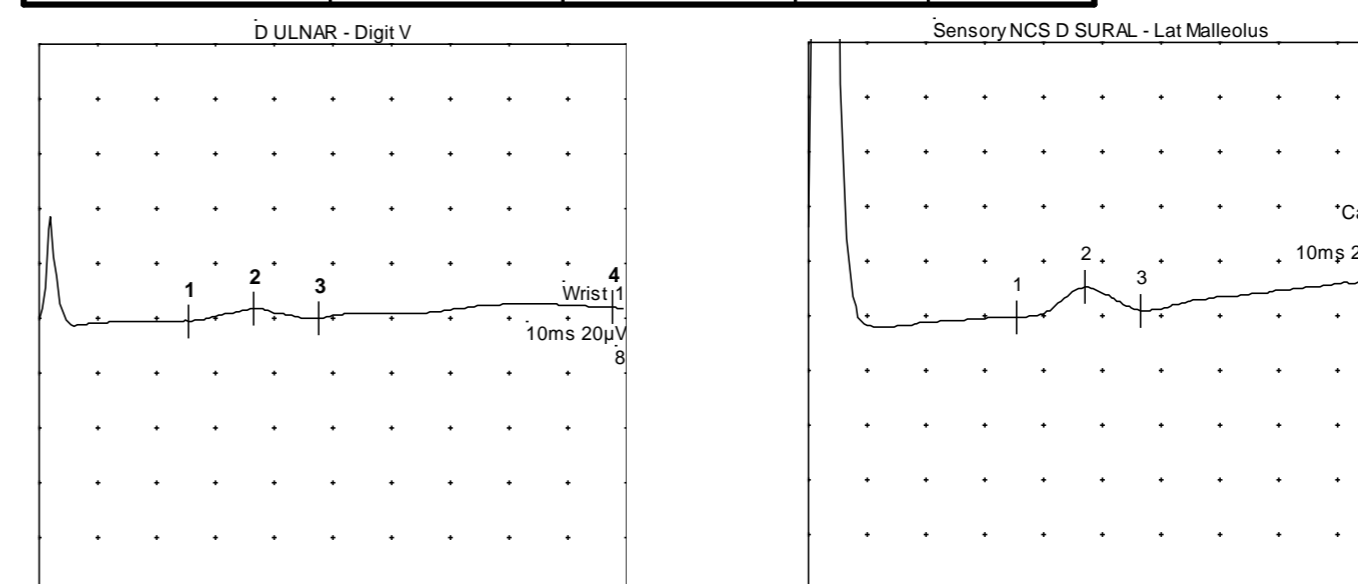
MRI and ENG results

BRAIN MRI: normal

EMG/ENG: moderate motor and sensory axonal-demyelinating polyneuropathy (Fig. 1-2-3)

| D ULNAR | Rec. Site | Peak Ampl (µV) | Vel. | Lat. |
|---------|---------------|----------------|------|------|
| Wrist | Digit V | 4,1 | 59,1 | 2,20 |
| D SURAL | | | | |
| | Lat Malleolus | 11,0 | 42,3 | 3,4 |

Fig. 1. Sensory NCS



| Nervo | Lat (ms) | Ampl (mV) | Velocity (m/s) | Dur (ms) |
|-----------------------|----------|-----------|----------------|----------|
| D COMM PERONEAL - EDB | | | | |
| Ankle | 3,2 | 6,2 | | 6,8 |
| Fib Head | 14,3 | 5,1 | 34,1 | 8,0 |
| Knee | 16,7 | 5,1 | 37,5 | 7,9 |
| S COMM PERONEAL - EDB | | | | |
| Ankle | 5,5 | 5,3 | | 6,3 |
| Fib Head | 15,6 | 4,9 | 36,8 | 6,9 |
| Knee | 17,9 | 4,7 | 38,3 | 6,6 |

Fig. 2 Motor NCS

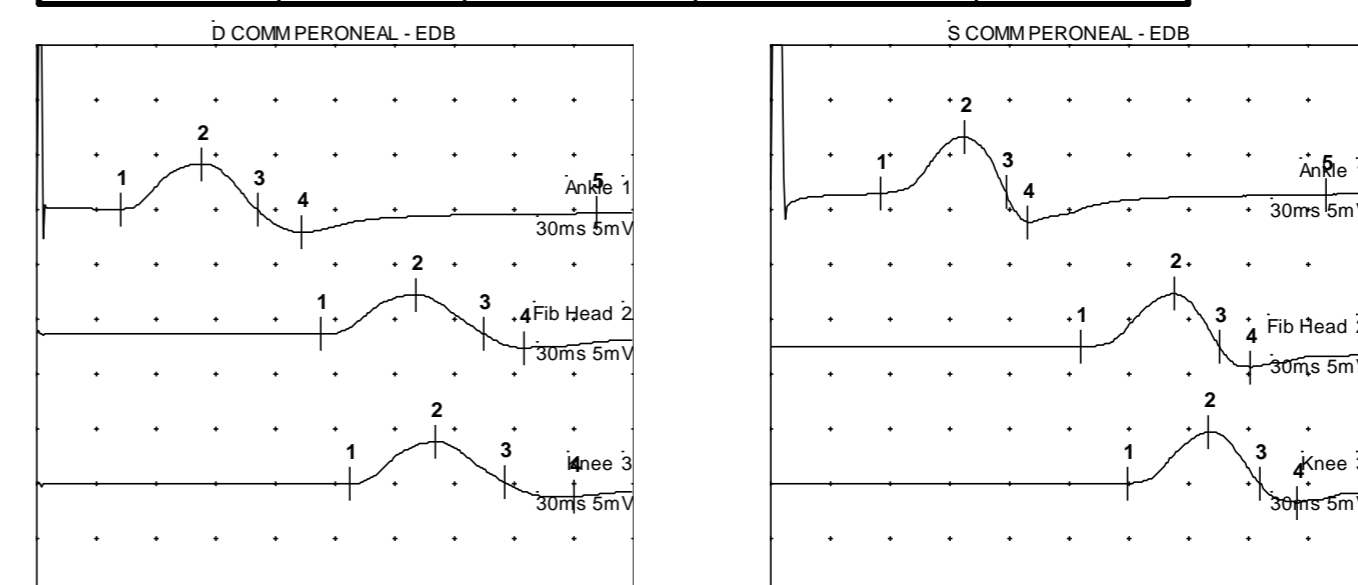
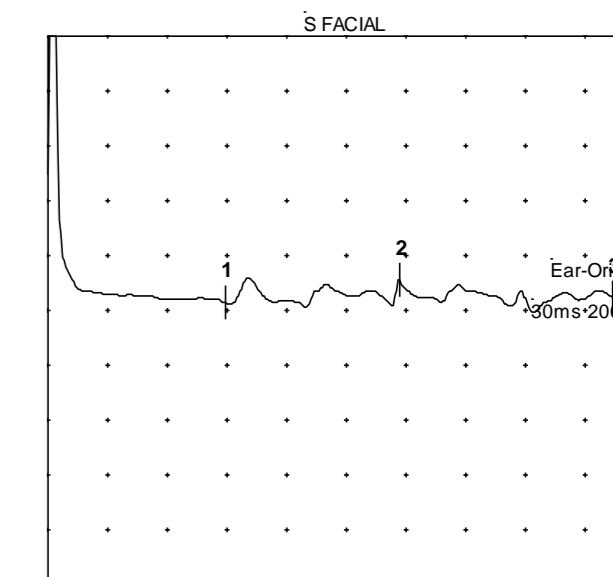


Fig. 3 Motor NCS

| VDC FACIAL S | | |
|----------------|--------------|--------------|
| Ear-Oris (ago) | Lat (ms) 8,9 | Amp (mV) 0,1 |



Therapies and clinical results

INTRAVENOUS IMMUNOGLOBULINS: ineffective
INTRAVENOUS METHYLPREDNISOLONE (high dose)
↓
ORAL PREDNISOLONE (50 mg daily)

full symptoms regression

Two relapses occurred over six months concurrently with corticosteroid tapering

↓
He is now treated with azathioprine and steroids (low dose) and the neurological examination is normal.

Conclusions

It is known that inflammatory process can overlap to diabetic neuropathy but we consider this patient interesting for his particular temporal trend, especially the subacute onset and the relapsing-remitting course, and for the selective clinical involvement of cranial nerves and autonomic system. The presence of such autoantibodies and the OCB mirror pattern corroborate the hypothesis of an autoimmune pathogenesis of the neuropathy.

References

- Fatehi F, Nafissi S, Basiri K, Amiri M, Soltanzadeh A. Chronic inflammatory demyelinating polyneuropathy associated with diabetes mellitus. J Res Med Sci. 2013 May;18(5):438-441. Review.
- Kawamura N, Dyck PJ, Schmeichel AM, Engelstad JK, Low PA, Dyck PJ. Inflammatory mediators in diabetic and non-diabetic lumbosacral radiculoplexus neuropathy. Acta Neuropathol. 2008 Feb;115(2):231-9

