

Federica Agosta,<sup>1</sup> Elisabetta Sarasso,<sup>1</sup> Aleksandra Tomić,<sup>3</sup> Silvia Basaia,<sup>1</sup> Nataša Dragašević,<sup>3</sup> Marina Svetel,<sup>3</sup> Massimiliano Copetti,<sup>4</sup> Vladimir S. Kostic,<sup>3</sup> Massimo Filippi.<sup>1,2</sup>

<sup>1</sup>Neuroimaging Research Unit, and <sup>2</sup>Department of Neurology, Institute of Experimental Neurology, Division of Neurosciences, San Raffaele Scientific Institute, Vita-Salute San Raffaele University, Milan, Italy; <sup>3</sup>Clinic of Neurology, Faculty of Medicine, University of Belgrade, Belgrade, Serbia; <sup>4</sup>Biostatistics Unit, IRCCS-Ospedale Casa Sollievo della Sofferenza, San Giovanni Rotondo, Foggia, Italy.

## INTRODUCTION

Primary dystonia has been associated with over 14 different genotypes, most of which follow an autosomal dominant inheritance pattern with reduced penetrance. The aim of this study is to investigate cortical thickness and white matter (WM) tract alterations in a large cohort of asymptomatic (DYT-A) and symptomatic (DYT-S) subjects carrying different DYT mutations.

## MATERIALS AND METHODS

This study included a large series of clinically manifesting and non-manifesting DYT mutation carriers. Specifically, we enrolled 9 DYT-A mutation carriers (4 DYT1, 4 DYT6, 1 DYT10) and 26 DYT-S mutation carriers (7 DYT1, 7 DYT6, 9 DYT5 or dopa-responsive dystonia, 1 DYT18, 1 DYT10, and 1 DYT25). 37 age- and sex-matched healthy controls (HC) were also studied (Table 1).

**Table 1.** Demographic and clinical findings in HC, DYT-S and DYT-A.

	HC	DYT-S	DYT-A	p*	p <sup>#</sup>	p <sup>§</sup>
N	37	26	9			
Age [years]	41.40 ± 12.24	39.65 ± 13.52	45.08 ± 15.17	1.00	1.00	0.87
Gender [F/M]	24/13	15/11	7/2	0.70	0.46	0.34
Education [years]	14.49 ± 2.54	12.12 ± 2.32	11.00 ± 5.13	0.007	0.008	1.00
FMS [0-120]	-	8.80 ± 8.70	-	-	-	-
UDRS [0-112]	-	14.80 ± 11.92	-	-	-	-

Abbreviations: HC= healthy controls; DYT-S= symptomatic dystonic patients; DYT-A= asymptomatic dystonic patients; F= females; M= males; FMS= Fahn-Marsden Scale; UDRS= Unified Dystonia Rating Scale. P values refer to ANOVA models, followed by post-hoc pairwise comparisons. p\*: DYT-S vs HC; p<sup>#</sup>: DYT-A vs HC; p<sup>§</sup>: DYT-S vs DYT-A. DYT5 patients were not included in FMS and UDRS statistics.

### MRI acquisition

1.5 T Philips Intera scanner

✓ T2-weighted spin echo and 3D T1-weighted fast field echo sequences.

✓ Diffusion Tensor (DT) MRI sequence with diffusion gradients applied on 65 noncollinear directions.

### MRI analysis

1. A surface based morphometry was used to assess cortical thickness (Freesurfer 5.3).
2. Tract-Based Spatial Statistics (TBSS) in FMRIB software library (FSL) was applied to assess white matter (WM) abnormalities.

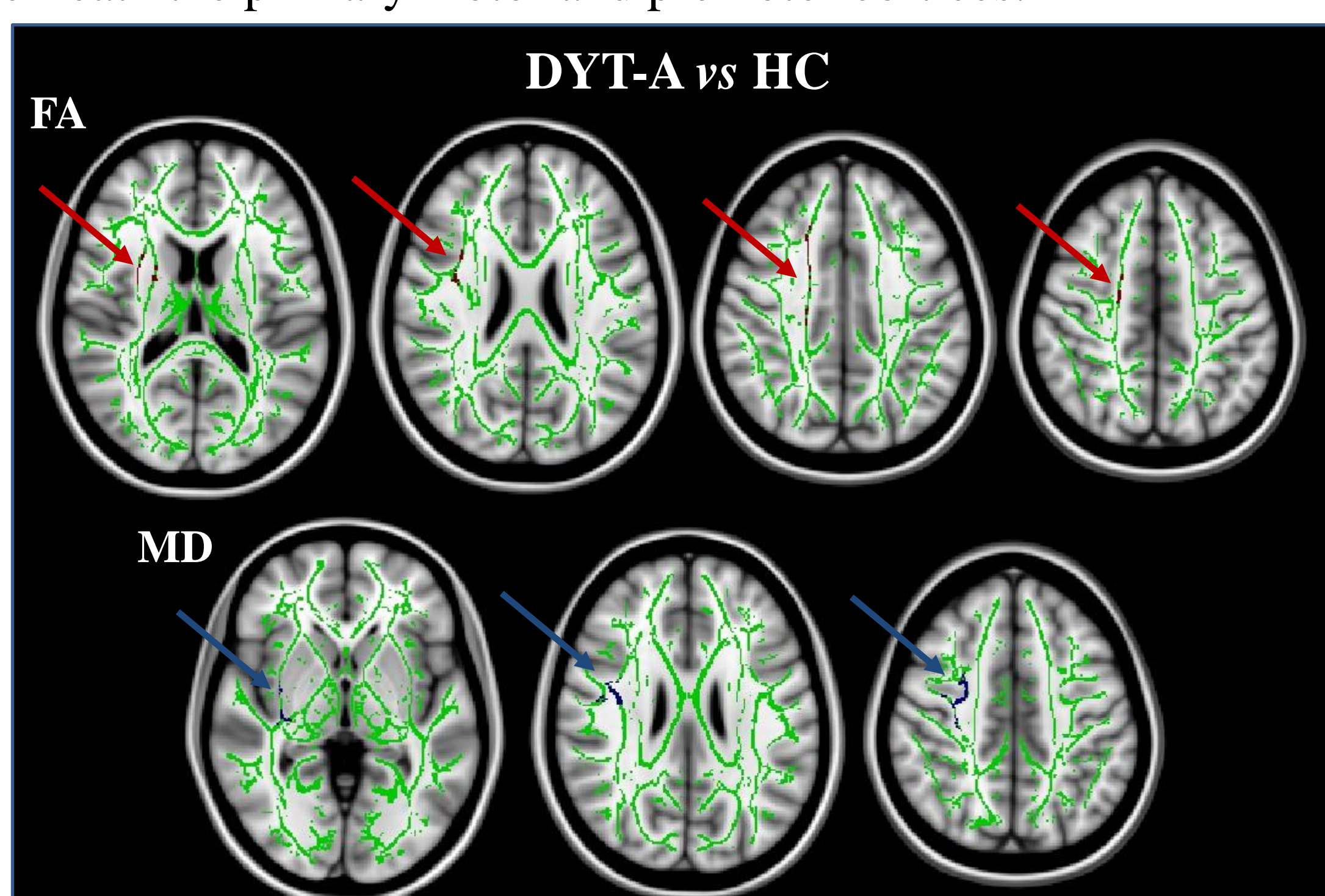
### Statistical analysis

✓ ANOVA models were used to assess GM and WM differences between HC DYT-S and DYT-A; p<0.05 FWE-corrected.

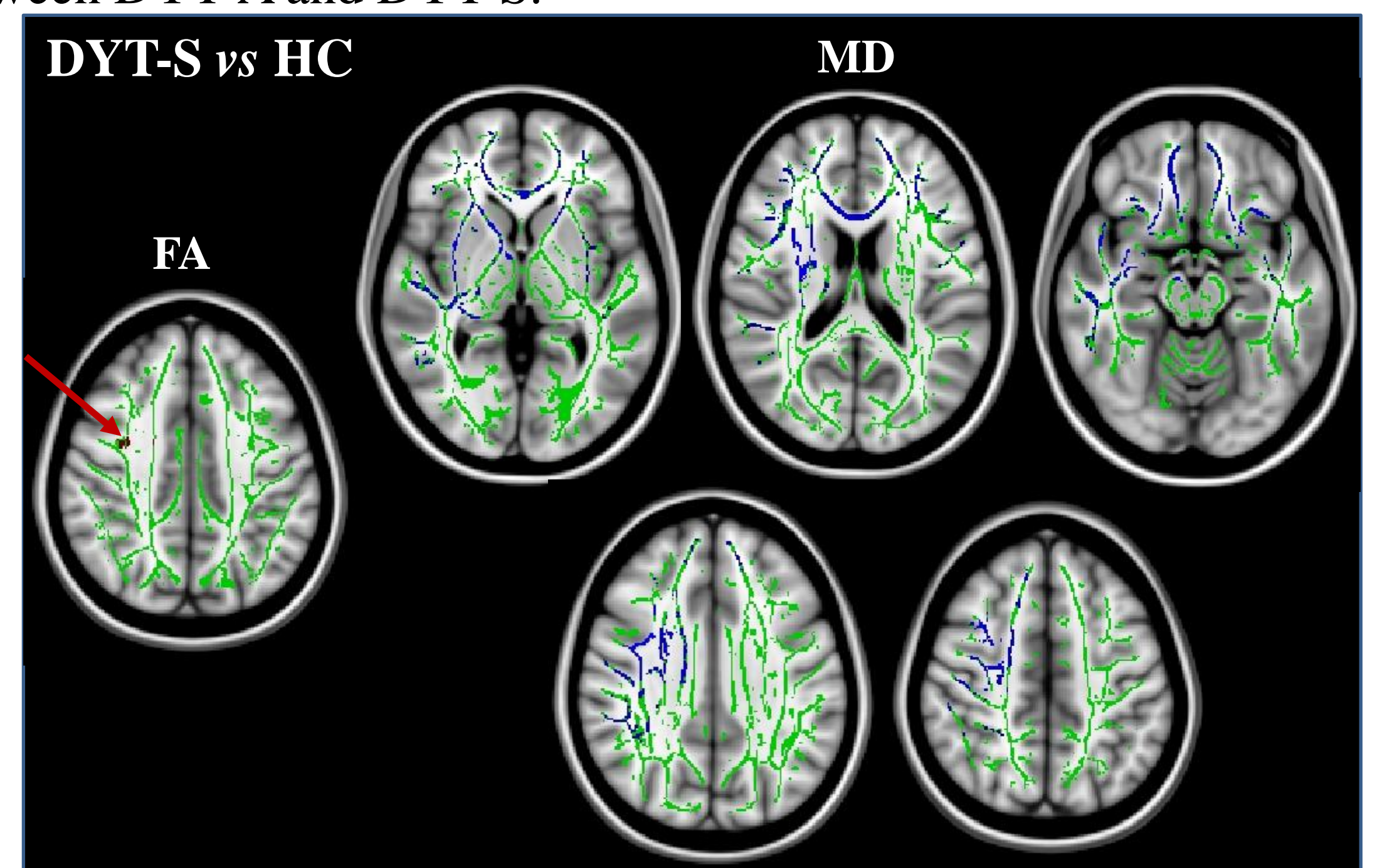
## RESULTS

### White matter damage

Compared to HC, DYT-A showed a pattern of increased mean (MD, blue) and radial (radD) diffusivity and decreased fractional anisotropy (FA, red) of the right internal capsule, corona radiate and WM underneath the primary motor and premotor cortices.



DYT-S relative to HC showed only a small region of decreased FA in the WM close to the right premotor cortex and a more widespread increase of MD, axial diffusivity, and radD involving the brainstem, internal and external capsule, WM underneath the primary motor and premotor cortices, anterior corpus callosum, and anterior temporal WM with a right side predominance. No DT MRI differences were observed between DYT-A and DYT-S.



### Grey matter atrophy

No cortical thickness abnormalities were found in DYT-A relative to HC. When compared to HC and DYT-A, DYT-S mutation carriers showed cortical thinning of the precentral, paracentral, middle and inferior frontal gyri bilaterally.

REGION	HC	DYT-A	DYT-S	p*	p <sup>#</sup>
R precentral gyrus	2.47 ± 0.10	2.49 ± 0.10	2.39 ± 0.18	<b>0.008</b>	<b>0.01</b>
L precentral gyrus	2.51 ± 0.09	2.54 ± 0.08	2.43 ± 0.19	<b>0.007</b>	<b>0.005</b>
R paracentral lobule	2.29 ± 0.11	2.29 ± 0.09	2.22 ± 0.15	<b>0.009</b>	<b>0.02</b>
L paracentral lobule	2.30 ± 0.10	2.32 ± 0.09	2.24 ± 0.14	<b>0.01</b>	<b>0.01</b>
R rostral middle frontal gyrus	2.30 ± 0.11	2.32 ± 0.12	2.28 ± 0.13	0.18	<b>0.04</b>
L rostral middle frontal gyrus	2.31 ± 0.10	2.35 ± 0.10	2.28 ± 0.13	<b>0.04</b>	<b>0.001</b>
R inferior frontal gyrus - pars orbitalis	2.58 ± 0.16	2.63 ± 0.20	2.59 ± 0.23	0.64	0.12
L inferior frontal gyrus - pars orbitalis	2.58 ± 0.18	2.60 ± 0.17	2.59 ± 0.18	0.63	0.20
R inferior frontal gyrus - pars triangularis	2.40 ± 0.14	2.42 ± 0.14	2.34 ± 0.18	<b>0.02</b>	<b>0.005</b>
L inferior frontal gyrus - pars triangularis	2.36 ± 0.11	2.39 ± 0.12	2.35 ± 0.17	0.29	<b>0.04</b>
R inferior frontal gyrus - pars opercularis	2.49 ± 0.12	2.53 ± 0.17	2.46 ± 0.17	0.06	<b>0.006</b>
L inferior frontal gyrus - pars opercularis	2.50 ± 0.11	2.52 ± 0.08	2.48 ± 0.11	0.16	<b>0.03</b>

p\*: DYT-S vs HC; p<sup>#</sup>: DYT-S vs DYT-A.

## CONCLUSIONS

This study revealed that specific WM structural imaging alterations can be identified in DYT-A, supporting the hypothesis that these changes are causative rather than an effect of the disorder. In addition, the analysis of the DT MRI eigenvalues revealing a different pattern of abnormalities in clinically manifesting (increased axD and radD) and non-manifesting (increased radD, unchanged axD) mutation carriers may allow to gain insight into the possible determinants of penetrance.<sup>1,2</sup> Whether different DYT mutations are associated with specific structural changes remains to be tested in larger groups of DYT mutation carriers.