

L. Vinciguerra<sup>1</sup>, C. Murr<sup>2</sup>, G. Pennisi<sup>1</sup>, J. Bösel<sup>2</sup>

<sup>1</sup>Neurology Clinic, Department G.F. Ingrassia - University of Catania

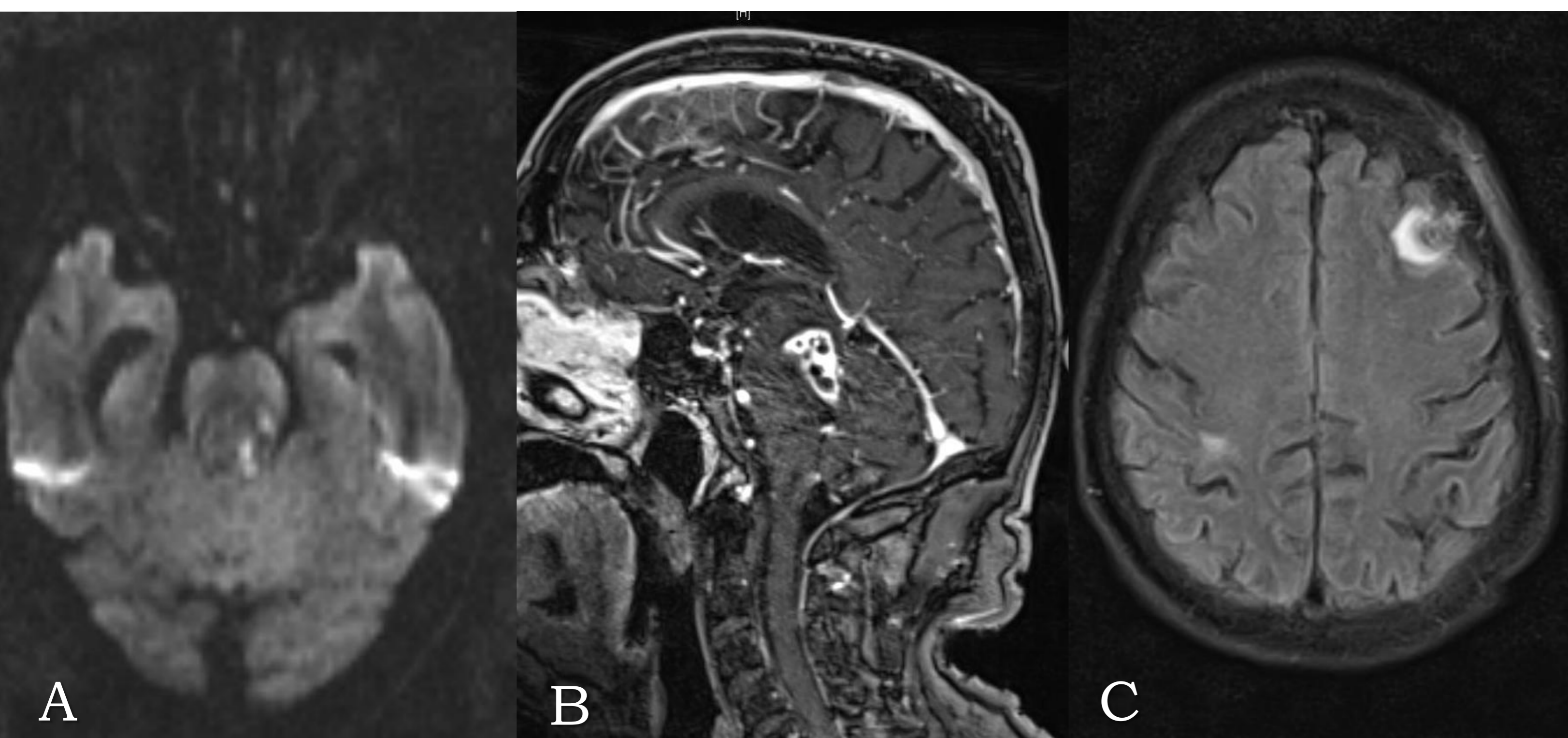
<sup>2</sup>Department of Neurology, Heidelberg University - Germany

## Background

Nocardiosis is a rare infection caused by the aerobic Actinomyces species of *Nocardia*. Brain abscess accounts for 1% to 2% of all cerebral abscesses. *Nocardia farcinica* appears more virulent than the other subspecies since the infection may cause disseminated lesions, tend to relapse and have a higher antibiotic resistance. Furthermore, Nocardiosis usually affects immunocompromised patients

## Case report

A 66-year-old immunocompetent man was admitted with a 6-week-history of night sweats and progressive fatigability followed by intermittent diplopia, left facial nerve palsy, aphasia, dysmetria, loss of balance, disorientation and drowsiness. Fever, headache, vomiting and seizures were denied.



### Biopsy

Branching gram-positive bacilli, confirmed as *Nocardia farcinica*.

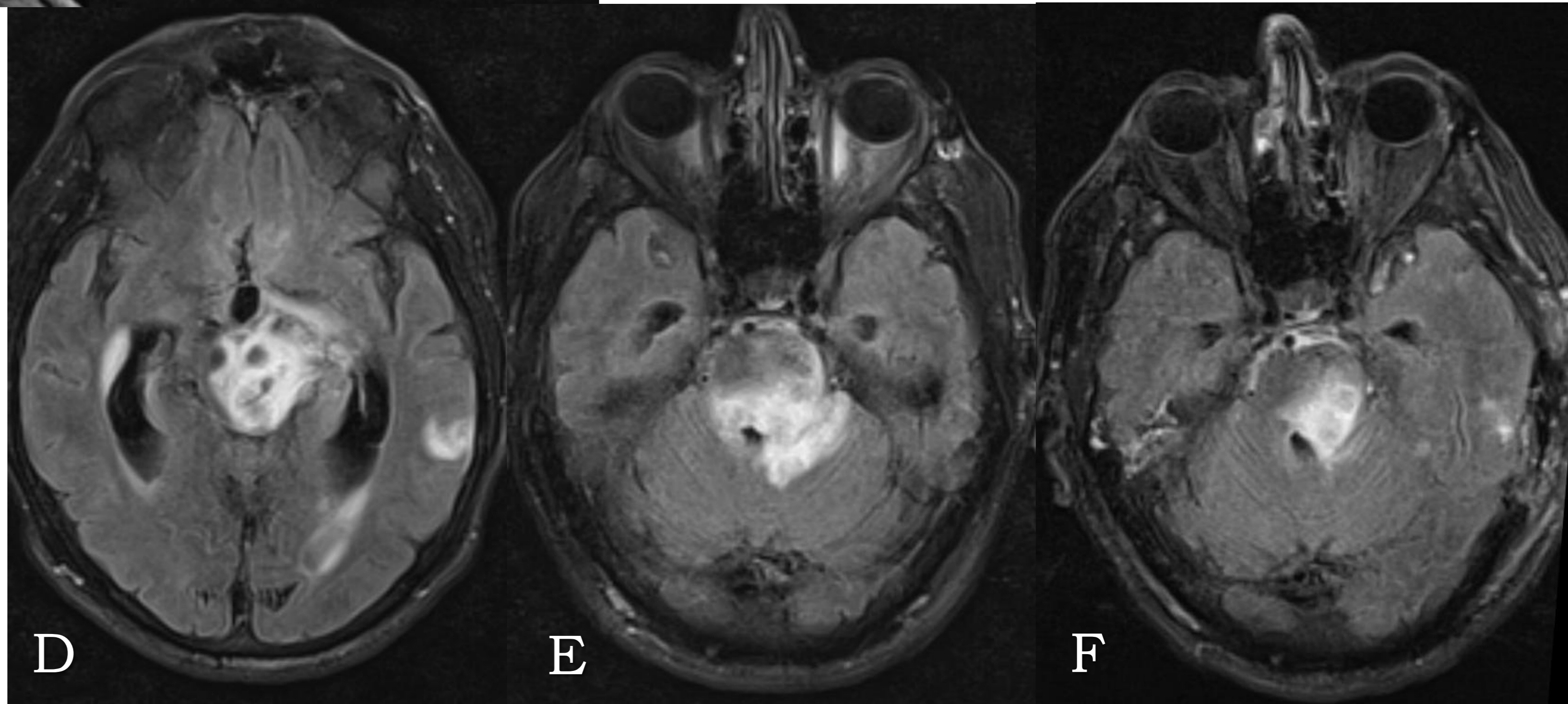
### Antibiotic therapy

Imipenem (1 g daily) and Cotrimoxazole (960/4800 mg daily) i.v.

### Magnetic Resonance Imaging

Partially diffusion restriction (A) and ring gadolinium enhancement of the brainstem lesions, with mild pachymeningeal thickening and enhancement (B).

Supratentorial, basal ganglia, cerebellar, and wide nodular confluent ponto-mesencephalic hyperintensities with an adjacent mass effect on FLAIR images before (C-E) and after one month therapy (F).



### Follow-up at 4 weeks

The patient was conscious but disorientated, he recovered from diplopia and facial nerve palsy, while aphasia, dysmetria and gait improved.

### Discussion

CNS nocardial infections may manifest as multiple brain or spinal cord lesions, diffuse cerebral inflammation, and meningitis. The mortality rates estimated for *Nocardia* brain abscess are 55% and 20% in immunocompromised and immunocompetent patients, respectively. Early identification, appropriate and prolonged treatment are crucial for a good prognosis.