

Clinical characteristics, Immunological accompaniments and Treatment Outcomes of Autoimmune Cerebellar Ataxia

V Damato, MD¹; G Silvestri, MD¹; M Luigetti, MD, PhD¹; A Evoli, MD¹; R Iorio, MD, PhD¹

1. Institute of Neurology, Catholic University, Rome, Italy

Introduction

Autoimmune cerebellar degeneration (ACD) is characterized by progressive disabling ataxia and, in most cases, its onset heralds an underlying tumor (1,2). ACD is typically associated with IgG antibodies (abs) binding to neuronal intracellular antigens and, less frequently, to antigens expressed on the neuronal plasma membrane. Treatment of the underlying cancer is critical, and abs characterization can direct the search for cancer.

Methods

We prospectively recruited patients >18 years of age, with subacute onset of cerebellar ataxia developed in < 6 months, with a history of cancer in the previous 4 years, and/or neural antibodies detected in the serum/CSF samples.

•Neural antibody testing

•Patients' serum and CSF samples were tested for neural-specific autoantibodies by the following methods:

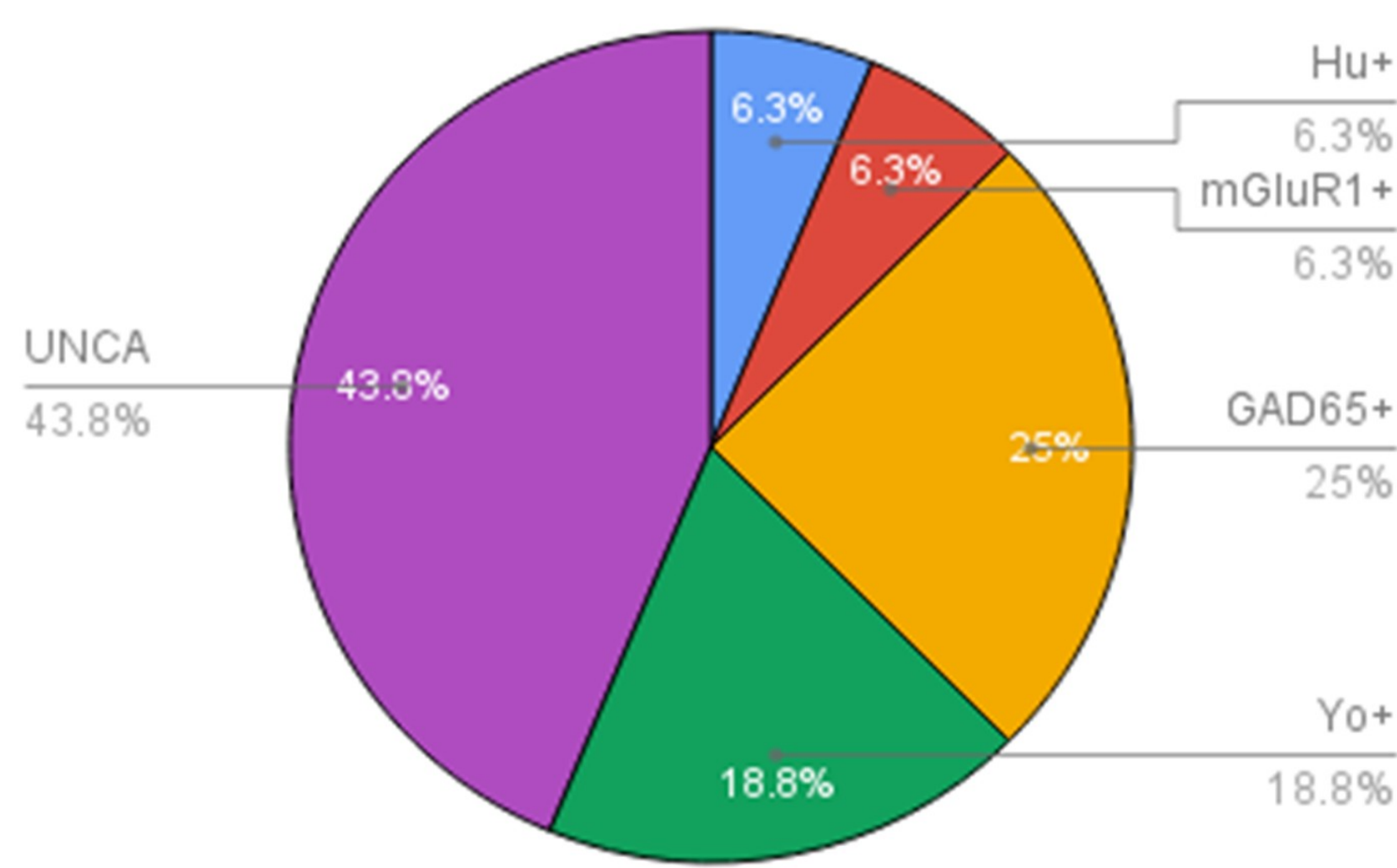
immunohistochemistry on a substrate of mouse brain, kidney and stomach; immunocytochemistry on live rat hippocampal neurons; cell-based assays for NMDAR-IgG, LGI1-IgG, CASPR2-IgG, GABA(A)R-IgG, mGluR5-IgG, mGluR1-IgG, DNER-IgG, Glycine receptor-IgG, DPPX-IgG; Radioimmunoassay for GAD65-IgG; immunoblot assays for Abs specific to onconeural antigens (Hu, Yo, Ri, CV2, amphiphysin, Ma1/2, Homer3, Zic-4)

Results

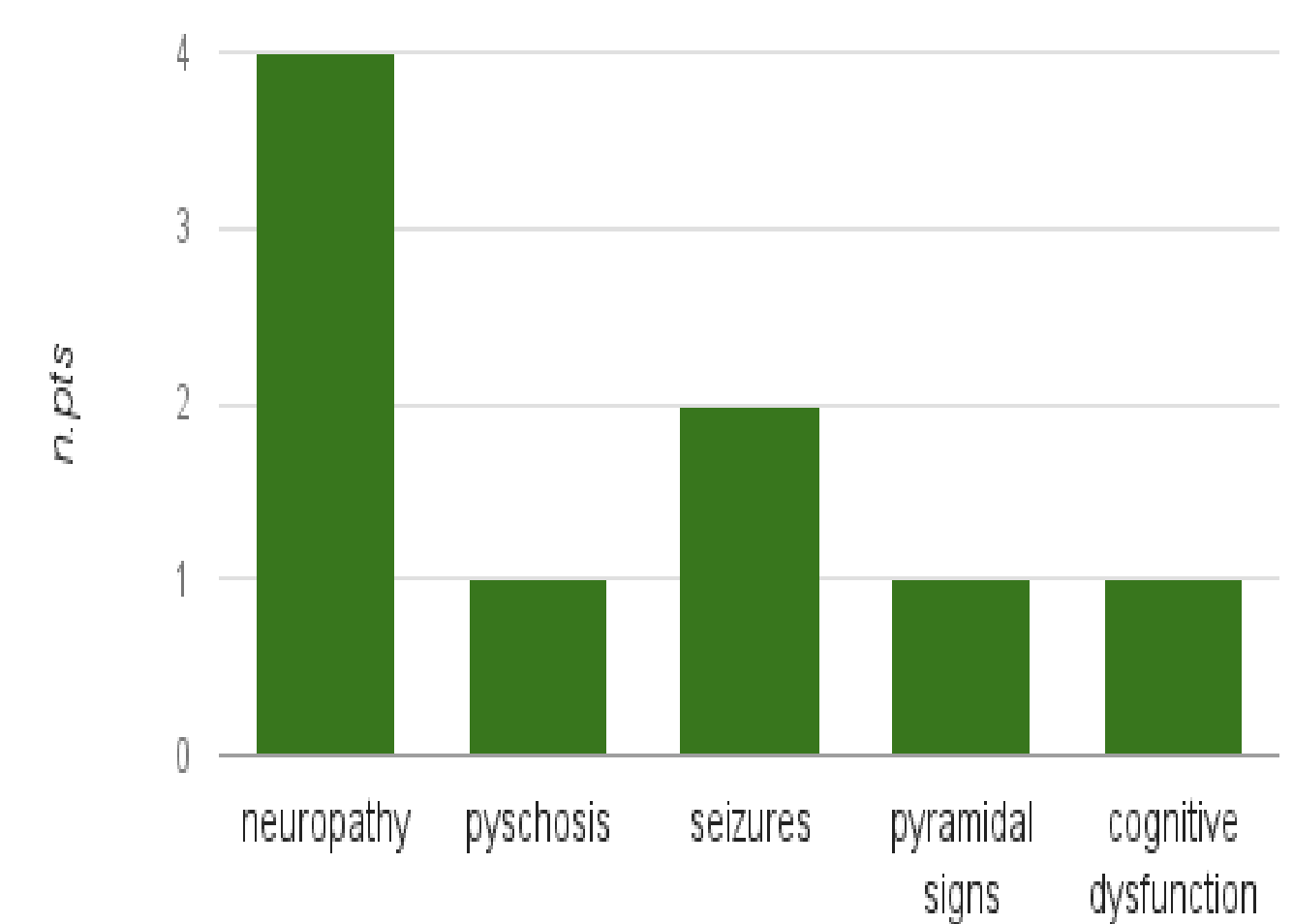
From January 2012 to December 2015, forty-five patients with subacute cerebellar ataxia were observed in our institution. Twenty-six patients were excluded from the study because other causes of ataxia were identified; two additional patients were excluded because they did not satisfy inclusion criteria. Nine of 17 patients were females (53%) and the mean age at the initial evaluation was 58 years. Neural autoantibodies were detected in 16/17 patients: GAD65-IgG, 4; Yo-IgG, 3; Hu-IgG, 1; mGluR1-IgG, 1; IgG binding unclassified antigens (UNCA), 7.

•A tumor was detected in 6/17 patients (35%): ovarian cancer in 3 patients (2/3 with Yo-IgG), breast cancer in 1 patient with Yo-IgG, prostate cancer in 1 patient with mGluR1-IgG and bladder cancer in 1 patient with UNCA-IgG. Ab specificities and extra-cerebellar symptoms are shown in Fig.3.

Fig.3 Neural specificity IgG frequency



Frequency of extracerebellar symptoms



Patients with paraneoplastic syndrome received appropriate oncological/surgical treatment. The scale for the assessment and rating of ataxia (SARA) was used to define the treatment outcome.

Patients with autoimmune cerebellar ataxia (AICA) had a significant lower SARA score before treatment compared to patients with paraneoplastic cerebellar ataxia (PNCA) ($p=0.003$) (Fig. 4A). Although SARA score did not decrease significantly in the total n. of patients after treatment in 6-12 months of follow-up (fig.4B), a trend for ataxia improvement was observed in patients with AICA at 12 months of follow-up (Fig.4D).

Fig.4

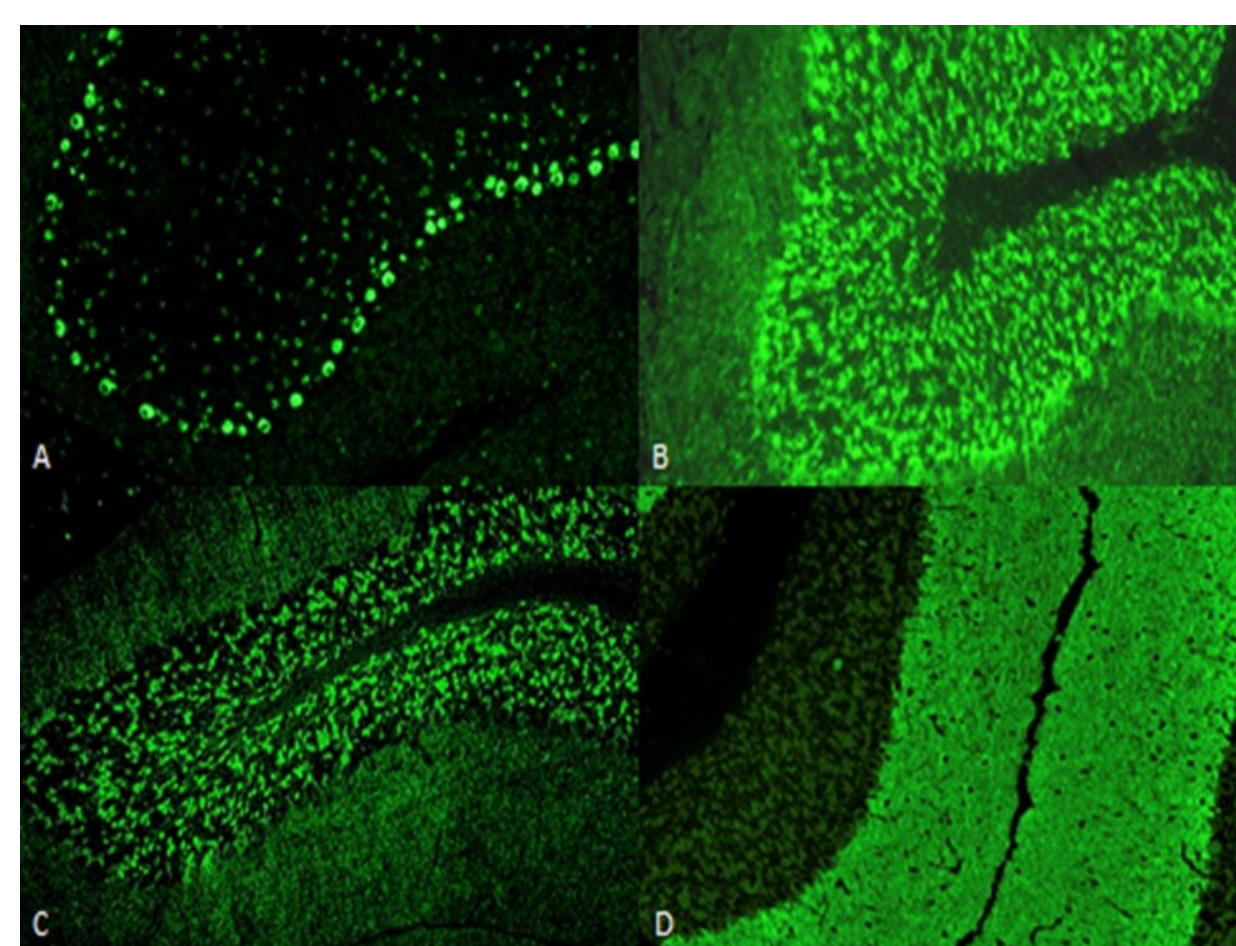
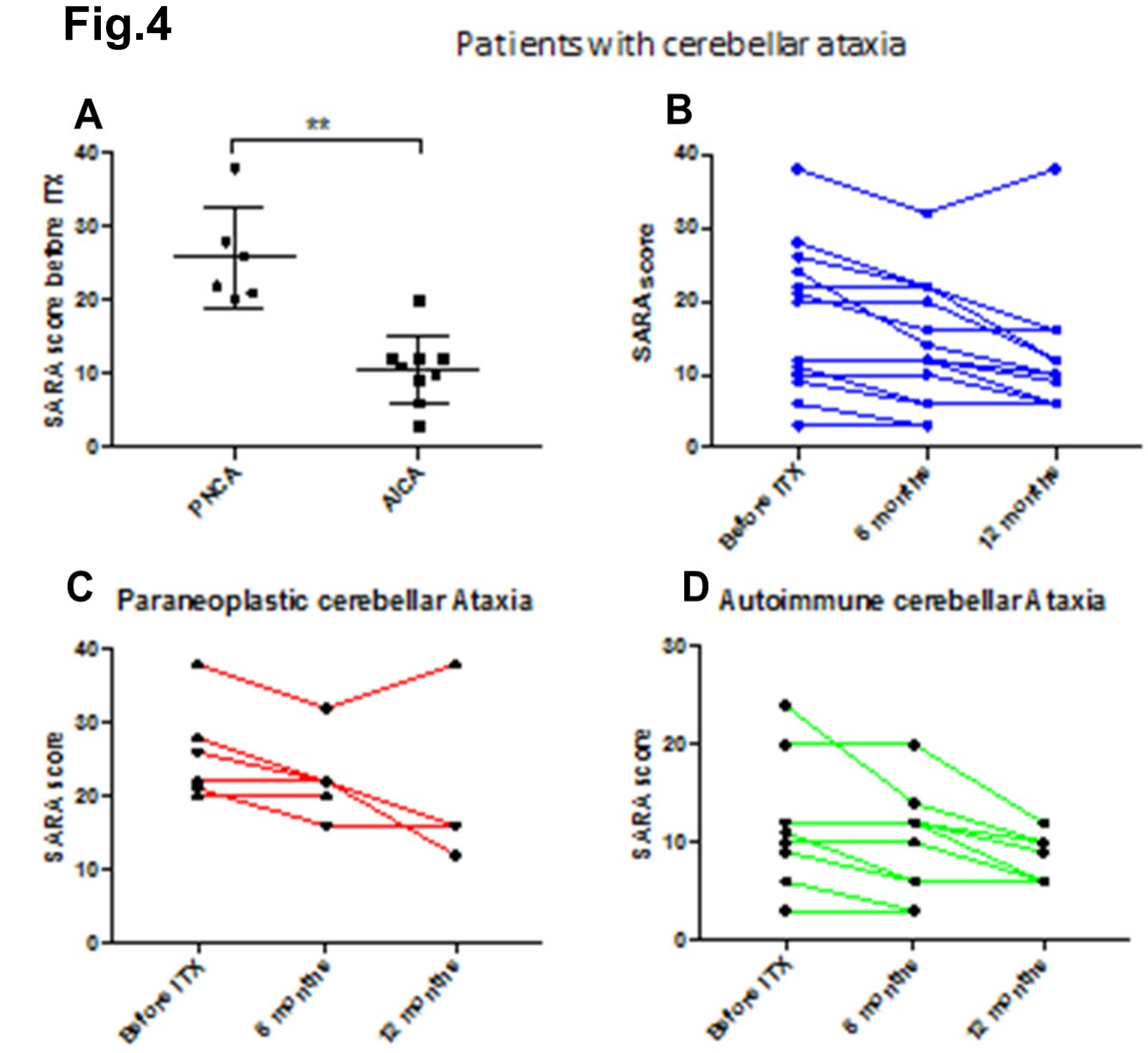


Fig.1 Immunoreactivity of Yo-IgG (A), GAD65-IgG (B), UNCA-IgG (C), mGluR1-IgG are showed (D) on mouse cerebellum sections.

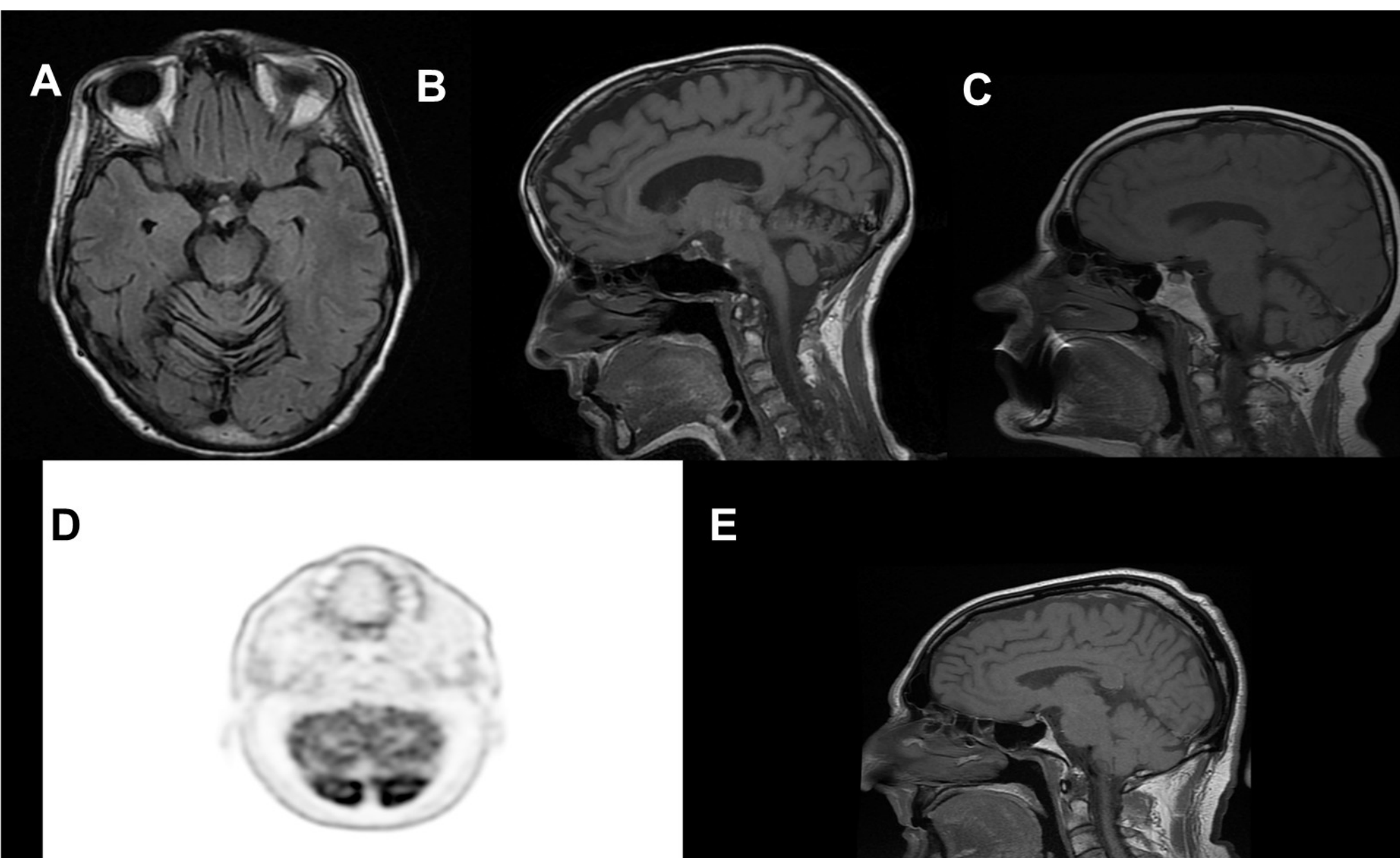


Fig.2

Brain MRI (T1-weight images; axial, A, sagittal, B, C, E) of 3 representative patients (with GAD65-IgG+, A-B; with Yo-IgG+, C; with cerebellar vermian atrophy. Brain PET images shows bilateral hypometabolism of cerebellum (D) with normal sagittal T1-weight MRI (E) in a patient with UNCA-IgG+

Conclusion

We observed a higher frequency of AICA (65%) compared to PNCA (35%). Consistent with previous studies, ACD was mostly associated to intracellular abs, however in 43% of patients IgG binding UNCA were detected. Half of the patients had a variety of coexisting extracerebellar signs, suggesting that cerebellar ataxia can be not the unique neurological manifestation. Although ACD is usually severe, improvement after immunotherapy can be observed particularly in patients with non-paraneoplastic disorder.

References

1. Paraneoplastic neurological syndromes. Graus F, Dalmau J. *Curr Opin Neurol.* 2012 ;25:795-801
2. Treatment of paraneoplastic cerebellar degeneration. Greenlee JE. *Curr Treat Options Neurol.* 2013 ;15:185-200