

T.Tallarico<sup>1</sup>, F. Novellino<sup>2</sup>, M.E. Caligiuri<sup>2</sup>, V. Saccà<sup>2</sup>, S. Barone<sup>1</sup>, A. Granata<sup>1</sup>, E. Filippelli<sup>1</sup>, C. Chiriaco<sup>2</sup>, A. Quattrone<sup>1,2</sup>, P. Valentino<sup>1</sup>.

<sup>1</sup> Institute of Neurology, University "Magna Graecia", Germaneto (CZ), Italy

<sup>2</sup> Neuroimaging Research Unit, UOS-IBFM, National Research Council, Catanzaro, Italy

## Objective

Multiple sclerosis (MS) is a central nervous system (CNS) disease involving both the white matter (WM) and grey matter (GM). Pathological studies have shown widespread GM demyelination, which involves the neocortex, thalamus, basal ganglia, hypothalamus, hippocampus, cerebellum, and spinal cord. Episodic memory, information processing speed and working memory are typically affected in MS patients, with episodic memory impairment being described in 43-70 % of them. The hippocampus has a critical role in episodic memory and visuospatial learning and consolidation. The aim of this study was to assess the pattern of whole and regional hippocampal atrophy in a large group of multiple sclerosis (MS) patients, and their correlations with neuropsychological impairment, in particular with Free and Cued Selective Reminding Test (FCSRT), a hippocampal-targeted paradigm.

## Materials and Methods

The study consisted of 61 (32 F e 29 M) MS patients (mean age:  $33.6 \pm 8.5$ ). All enrolled subjects underwent an accurate neurological and neuropsychological examination, including Short battery of Rao and FCSRT performed by an experienced neuropsychologist unaware of clinical and MRI results. Brain information was acquired using a 3.0-Tesla scanner. All subjects underwent the same MRI protocol, including whole-brain T1-weighted sequence. To identify regional differences in hippocampal morphology, we used shape-analysis in correlation mode to assess association correlations between hippocampal shape and FCSRT scores across subjects.

## Results

We found a significant correlation between delayed free recall (DFR) item of FCSRT and hippocampal shape that mapped to the ventral area of the head corresponding to the subiculum in the left hippocampus.

## Discussion & Conclusions

We investigated the regional anatomical distribution of hippocampal shape changes and their correlation with performance in hippocampal-dependent memory tasks (FCSRT) in a sample of MS patients. We showed a significant correlation between the subicular region and the performances in FCSRT, in particular the DFR. The hippocampi are involved in episodic and declarative memory, but the precise structure of the mnemonic physiological process within the hippocampus remains widely debated. The subiculum plays an important role in spatial navigation and mnemonic processing; moreover, it is the major synaptic relay for most of the CA1 neurons and the last synaptic efferent relay of the hippocampus prior to the cortex. In particular, the left hippocampus is involved in episodic memory, contributing to storage of verbal material. These results may help explain how memory processing is associated with the function of specific hippocampal subfields and improve the knowledge of specific MS-related mnemonic profile.

## References:

- 1.G.Longoni, M.A Rocca, E.Pagani, GC Riccitelli, B.Colombo, M. Rodegher, A.Falini, G.Comi, M.Filippi. Deficits in memory and visuospatial learning correlate with regional hippocampal atrophy in MS. *Brain Struct Funct.* 2015 220: 435-444.
2. A.Cerasa, P.Valentino, C.Chiriaco, D.Pirritano, R.Nisticò, CM Gioia, M.Trotta, F.Del Giudice, T.Tallarico, A.Quattrone.MR imaging and cognitive correlates of relapsing –remitting multiple sclerosis patients with cerebellar symptoms. *J.Neurol.* 2013 260: 1358-1366

Fig. 1

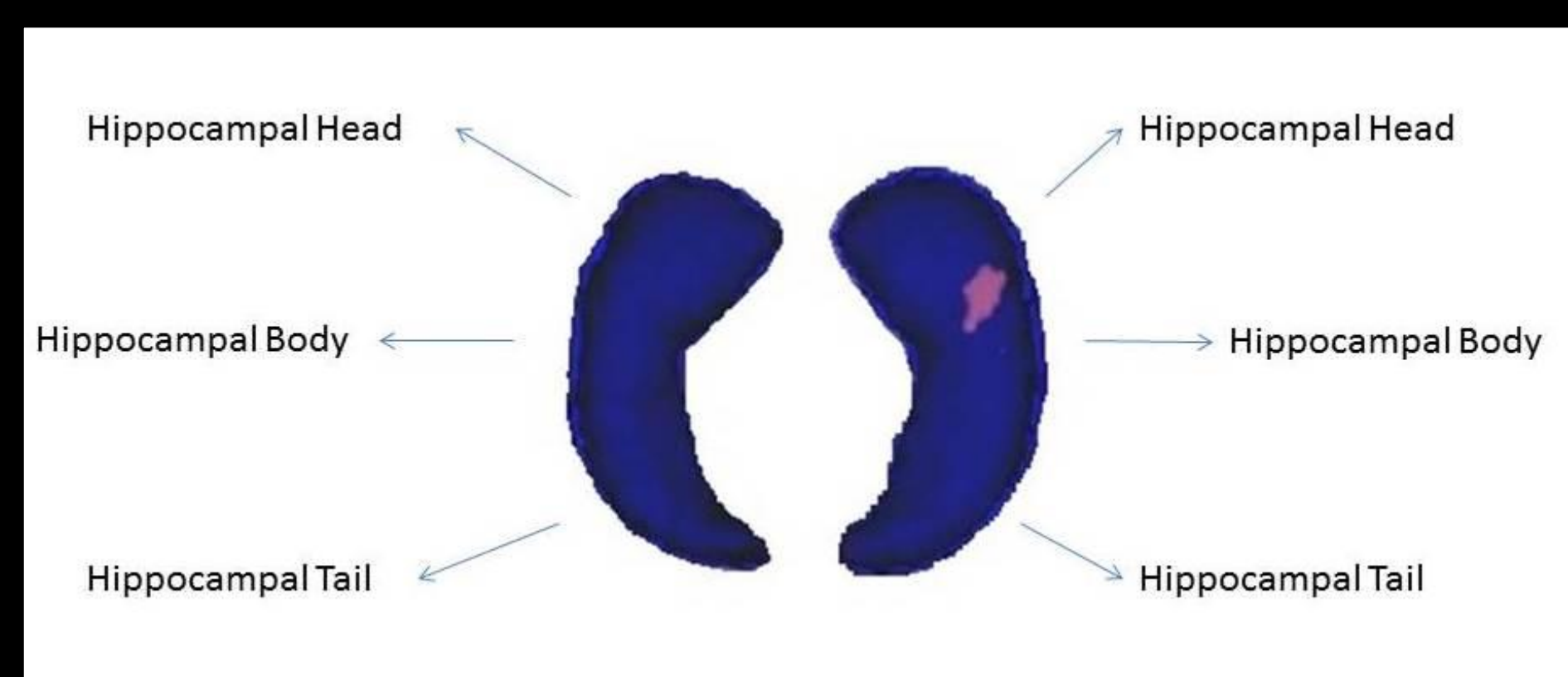


Fig. 2

