

# Severe choreiform movements in vegetative state related to hypoglycemic coma

M. Rossi<sup>1,2</sup>, C. Fassio<sup>1</sup>, G. Bellaviti<sup>1</sup>, A. Carolei<sup>2</sup>, C. Pistarini<sup>1</sup>

<sup>1</sup> IRCCS Fondazione Salvatore Maugeri, Department of Neurorehabilitation, Pavia

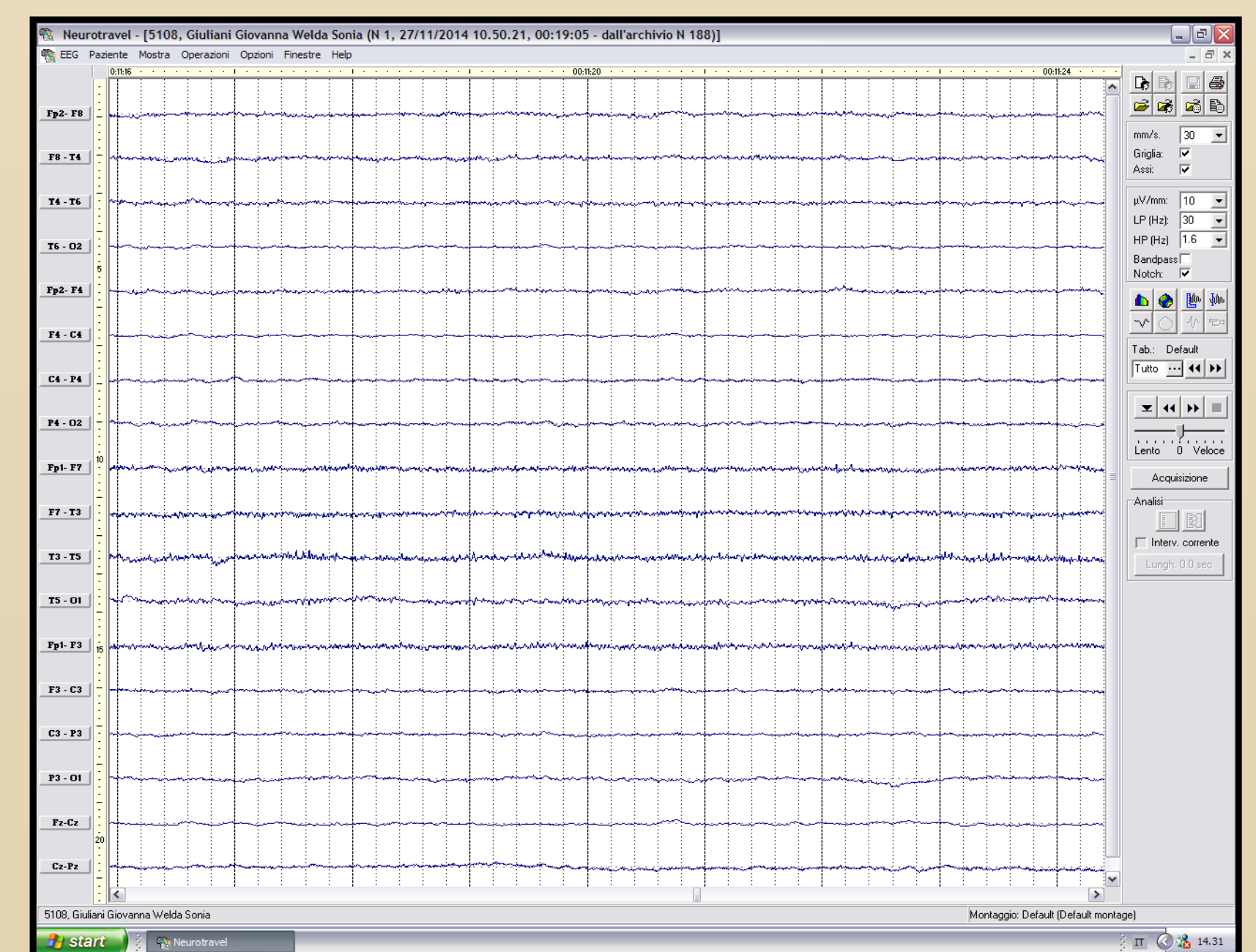
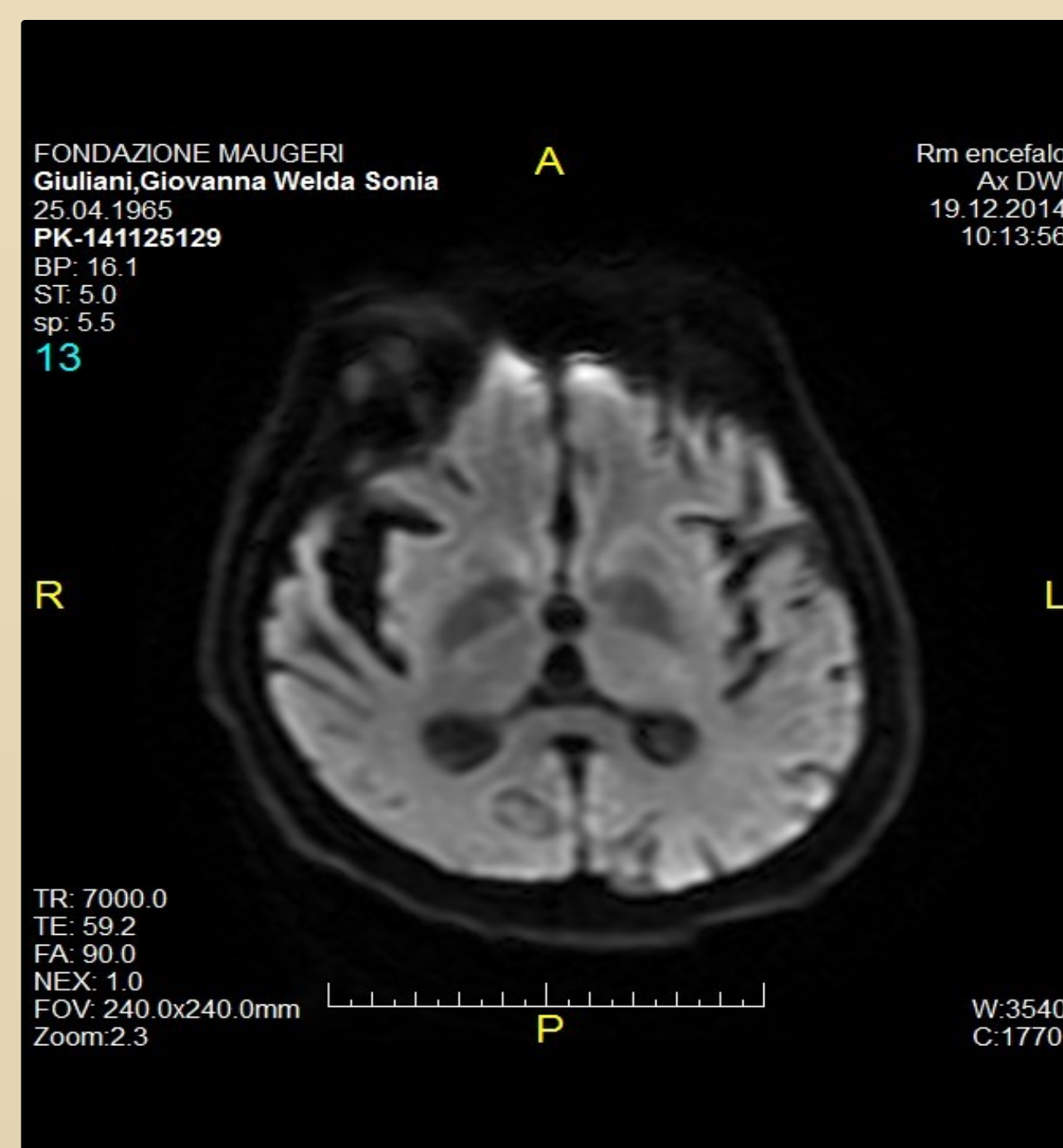
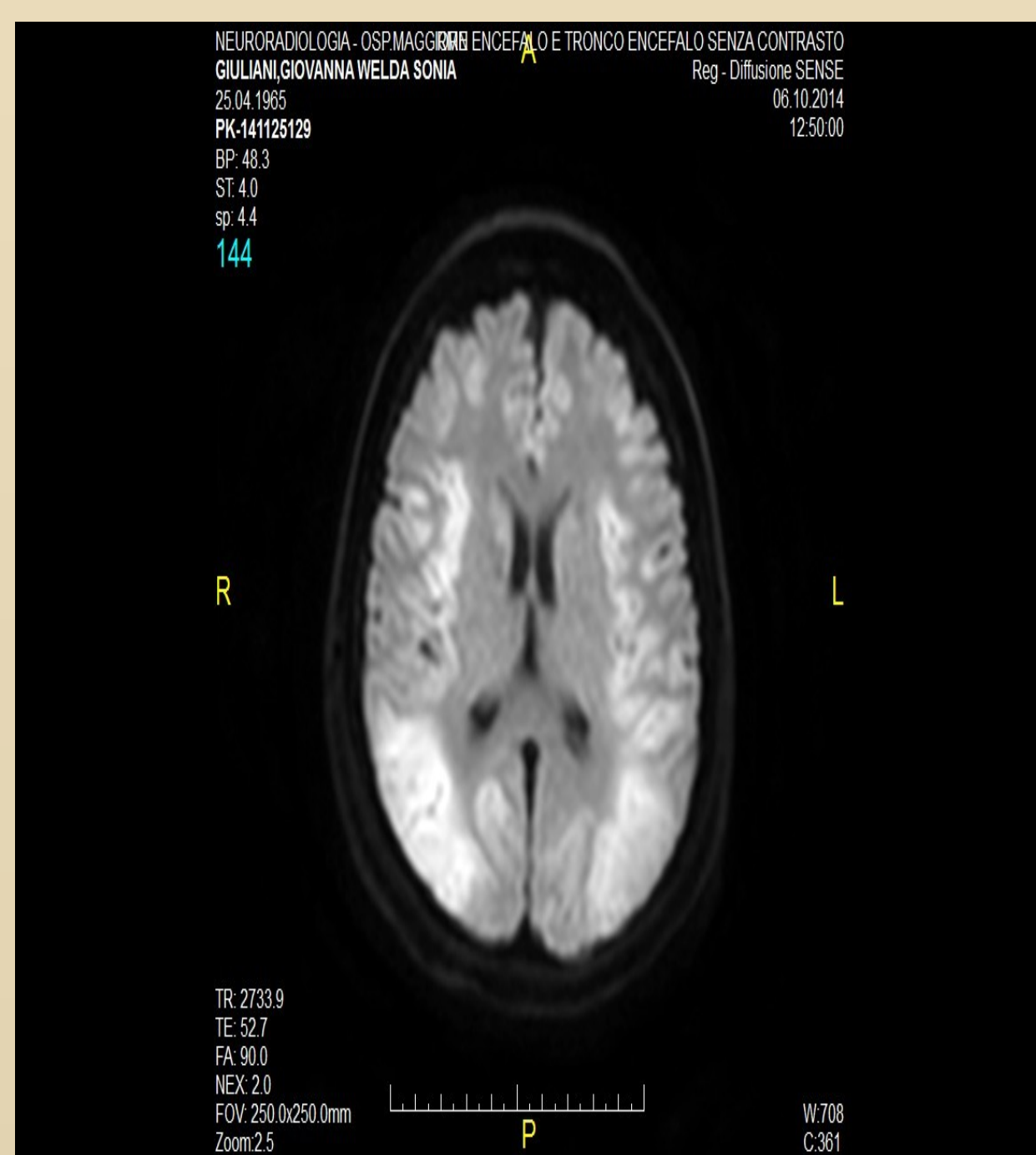
<sup>2</sup> Department of Neurology, University of L'Aquila (L'Aquila)

## BACKGROUND

We describe a patient in a vegetative state secondary to hypoglycemic coma who developed bilateral choreiform movements with only poor response to usual therapies.

## CASE REPORT

A 49-year-old woman leaving alone, was found unconscious after 2 days her relatives had not her news. The patient had no exposure to carbon monoxide, no history of cardiac arrest and she was treated for diabetes mellitus with insulin therapy. She usually neglected her health and did not adhere to regular medical follow-up. Emergency workers found normal respiratory rate, blood pressure and SpO<sub>2</sub>; Glasgow Coma Scale score (GCS) was 4/15. After first aid, she was transported to an Intensive Care Unit. Electrolytes, liver and renal function were normal. Brain MRI-DWI revealed diffuse high signals on the cerebral cortex bilaterally, indicating a toxic-metabolic involvement, compatible with hypoglycemic damage; ECG and echocardiogram were normal; CSF analysis was normal. EEG showed a non-convulsive status epilepticus, responsive to phenytoin and levetiracetam. After 14 days she was discharged from the Intensive Care Unit and admitted to our Rehabilitation Unit. After two months, bilateral choreiform involuntary movements appeared, firstly in response to tactile or nociceptive stimuli, and then occurring spontaneously. Brain MRI showed expansion of the ventricular system and of the subarachnoid spaces secondary to atrophy, without evident new focal areas of signal alterations in any sequences. Neuroleptic therapy with risperidone 3 mg twice a day and clonazepam 3 mg twice a day has been introduced with only poor clinical benefit.



## DISCUSSION

Neurological manifestations of hypoglycemia can be wide and may include seizures and hyperkinetic movement disorders. These symptoms can be temporary or permanent sequelae. Although there are several case reports of transient chorea in the setting of hypoglycemia, no cases have been reported in which bilateral choreiform movements appeared within such a protracted time interval from the causative event in a vegetative state derived from hypoglycemic coma. Moreover, this case was worth reporting because the hyperkinetic movements were not apparently associated with characteristic brain MRI signal alterations in focal areas as the basal ganglia, were stimulus sensitive, and only poor responsive to high-doses of a combination of a neuroleptic with a benzodiazepine.

## CONCLUSION

Severe hypoglycemia leading to coma and vegetative state may be followed by bilateral choreiform movements appearing months after the first event, and resistant to usual therapy. Moreover, in our case no typical correlations between brain MRI imaging and hyperkinetic movements were found.

## References

1. Cryer PE. Hypoglycemia, functional brain failure, and brain death. *J Clin Invest.* 2007;117(4):868-70.
2. Guerrero WR, Okun MS, McFarland NR. Encephalopathy, hypoglycemia, and flailing extremities: a case of bilateral chorea-ballism associated with diabetic ketoacidosis. *Tremor Other Hyperkinet Mov (N Y)* 2012;2:pii:tre-02-58-235-1.