

# INCOERCIBLE HICCUP AS FIRST SYMPTOM OF NEUROMYELITIS OPTICA SPECTRUM DISORDERS SELECTIVELY INVOLVING THE BRAINSTEM. A CASE REPORT.

A Sanna<sup>a</sup>, P Ferrigno<sup>b</sup>, D Murgia<sup>b</sup>, D Manca<sup>b</sup>, F Marrosu<sup>a</sup>, M Melis<sup>b</sup>

<sup>a</sup>Dept. Of Public Health, clinical and molecular medicine, University of Cagliari, Cagliari, Italy. <sup>b</sup>Department of Neurology and Stroke Unit, AO Brotzu, Cagliari

## Introduction

Neuromyelitis optica spectrum disorders (NMOSD) is a group of inflammatory demyelinating disorders, mediated by pathogenic autoantibodies (NMO-IgG) against astrocyte aquaporin-4 (AQP4), the main water channel of the central nervous system (CNS). MRI studies of NMOSD show that brainstem lesions can occur isolated or as rostral extension of cervical myelitis.

## Objective

We report a case of a 69 year old woman, presenting with incoercible hiccup, followed by worsening dysphagia associated with vomiting and dysarthria. The patient underwent gastroenterological investigation such as gastroscopy and abdominal CT scan revealing an adenomatous polyp. After few weeks she developed an acute clinical picture characterized by hypoesthesia and ataxic hemiparesis on the right side. Neurological examination disclosed horizontal nystagmus and hyporeflexia.

Brain MRI scan displayed a hyperintensity in T2 weighted and DWI image with contrast enhancement in the rostral part of medulla oblongata; inflammatory, neoplastic and nutritional etiology was discussed. After 3 days the patient presented dysphonia and acute respiratory failure, with necessity of mechanical ventilation in intensive care unit.

Intravenous methylprednisolone (1g/day for 5 days) and following treatment with IG ev (25 g/day for 5 days) were administered with progressive clinical improvement. At discharge neurological examination showed mild dysphagia and slight ataxia, with complete clinical and radiologic resolution in the following 6 months.

One year after a new episode characterized by hiccup and right peri-oral paresthesia occurred; MRI finding of T2 weighted images showed a pontine lesion. The patient was treated with methylprednisolone 1 g ev for 5 days. NMO antibodies were found, leading to the diagnosis of NMOSD. Therapy with Azathioprine 150 mg/daily and Prednisone 50 mg/daily was started with progressive clinical and radiological improvement.

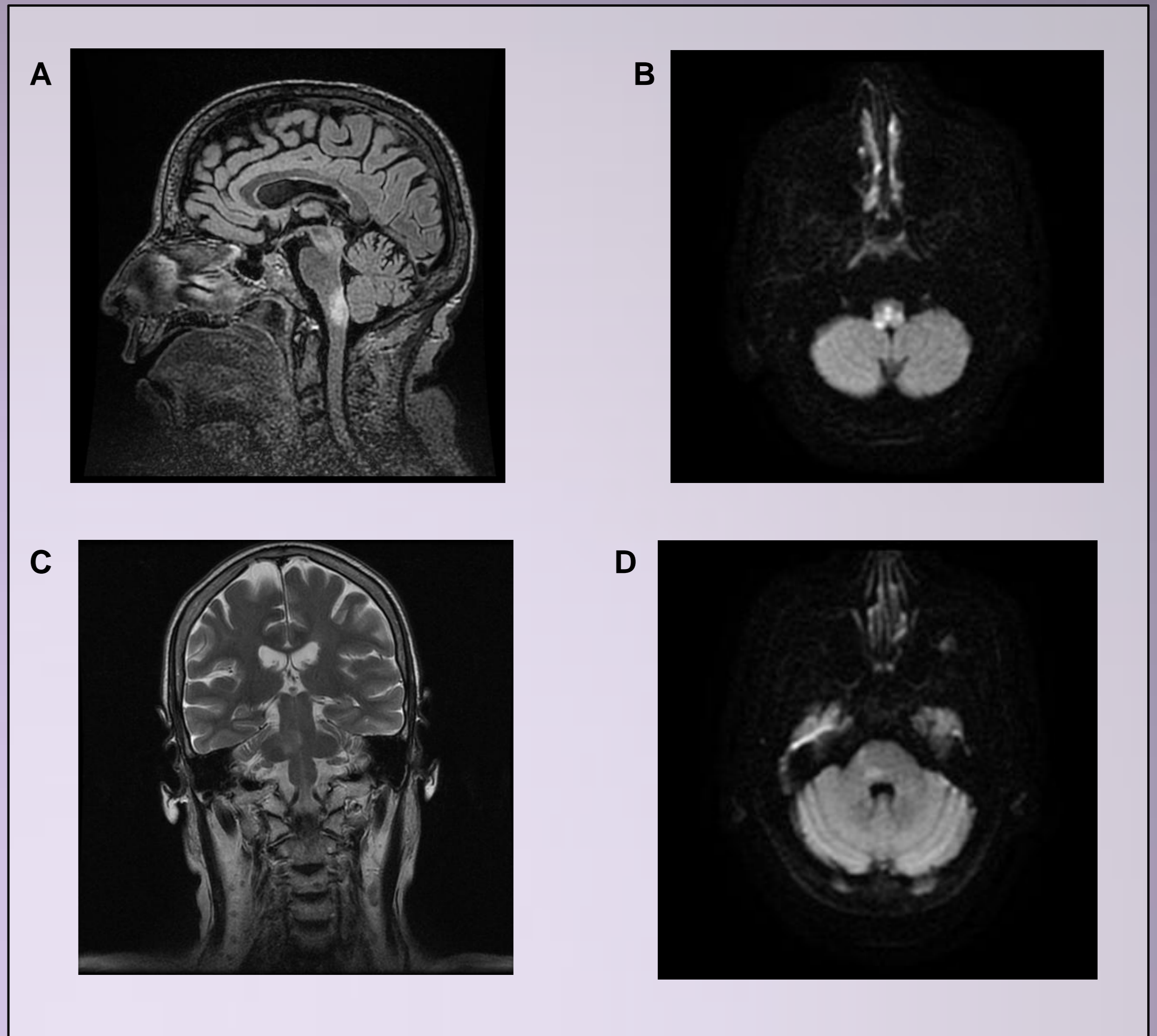


Figure legend: Sagittal brain T2 weighted (A) and axial DWI (B) MRI showing a focus of high signal in the posterior medulla. Coronal brain T2 weighted FLAIR (C) and axial DWI (D) MRI showing a pontine lesion.

## Discussion

Here is described a case of a patient presenting with incoercible hiccup, an atypical and non specific CNS symptom with a rapid clinical evolution of the disease. This report underlines the possible selective involvement of the brainstem in the onset of NMOSD which should be promptly recognized and treated in order to prevent severe evolution of the disease.

## Bibliography

- Wingerchuck M et al, The spectrum of Neuromyelitis optica, *Lancet neurology* 2007; 6:805-15  
Patel V et al, Spectrum disorder of Neuromyelitis Optica in a patient presenting with intractable vomiting and hiccups, transverse myelitis and acute encephalopathy. *Journal of clinical neuroscience* 19 (2012): 1576-1578.  
Kim HJ et al, MRI characteristics of neuromyelitis optica spectrum disorder, *Neurology* 2015; 84:1165-1173