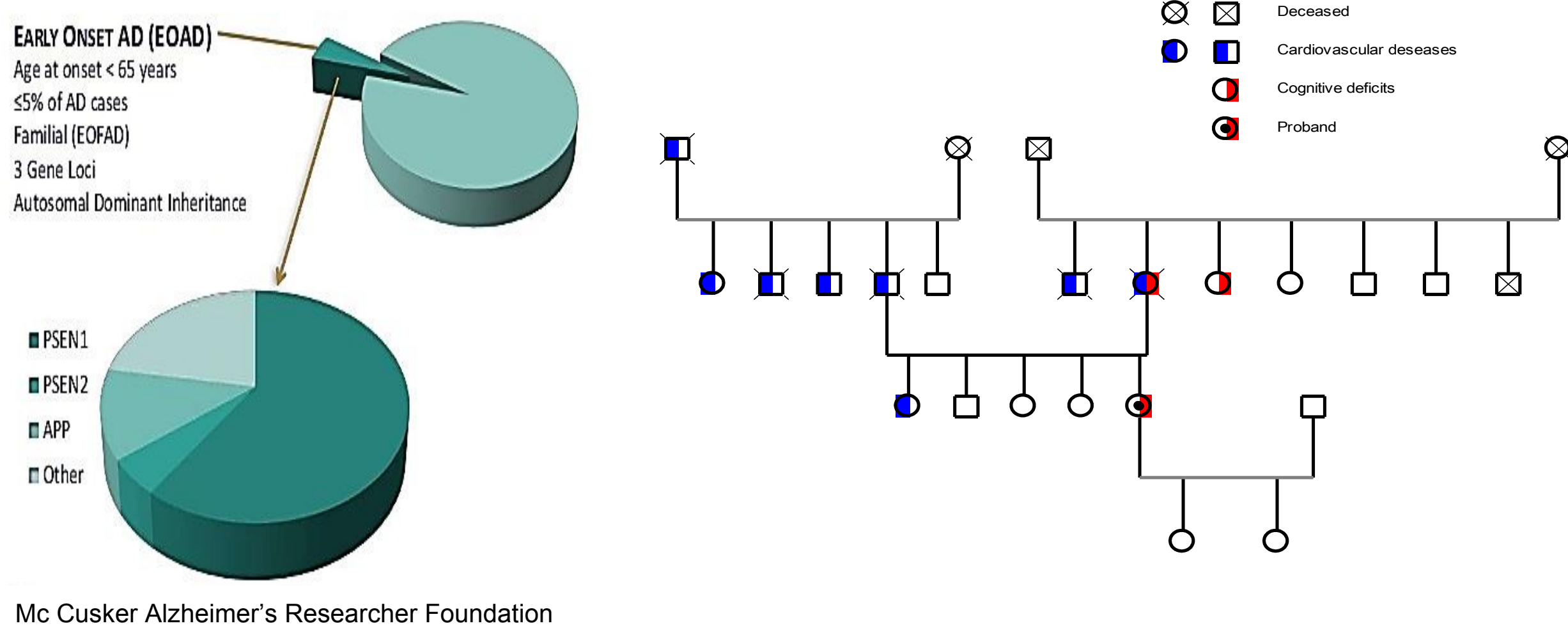


V Vacchiano¹, M Stanzani Maserati², A Bartoletti Stella¹, F Oppi², S Piras², P Parchi^{1,2}, S Capellari^{1,2}, R Liguori^{1,2}.

¹ Department of Biomedical and Neuromotor Sciences, University of Bologna, Bologna, ² IRCCS Institute of Neurological Sciences, Bologna, Italy

Objective

Mutations in three genes (*PSEN1*, *PSEN2*, and *APP*) have been identified in patients with early-onset Alzheimer's disease (EOAD). Most cases are due to mutations in the *PSEN1* gene, whereas mutations in the *APP* and *PSEN2* genes are rare. We present a 49-year-old woman carrying a *PSEN2* mutation



Mc Cusker Alzheimer's Researcher Foundation

Materials and Methods

We performed clinical, neuropsychological (NPS), neuroimaging, CSF and genetic testing.

Cognitive deficits recurred in the mother and in a maternal aunt, deceased at 65 and 80 years, respectively.

A Next Generation Sequencing panel (Illumina) containing 16 dementia associated genes (*PRNP*, *PSEN1*, *PSEN2*, *APP*, *PGRN*, *TARDBP*, *VCP*, *FUS*, *CHMP2B*, *SERPINI1*, *CSF1R*, *TYROBP*, *NOTCH3*, *ITM2B*, *MAPT* e *TREM2*) was performed to verify the presence of dementia-linked mutations.

Results

The patient reported right transient sensorimotor hemi-syndrome at 47 years of age. Seven months later, a second episode (lasting 20 min) was characterized by perioral paresthesia and deviation of the buccal rhyme.

In the following two years, she referred deficits of anterograde memory, incongruous behaviors, difficulty in finding words, and two short episodes characterized by difficulty in recognizing familiar places.

Three months after the onset, NPS testing showed MMSE score of 24.62. One year later, NPS testing underscored an important worsening (MMSE score 19.9/30);

FDG- PET imaging revealed a mild and symmetrical cortical hypometabolism in the temporal mesial regions; brain MRI nonspecific white matter hyperintensities.

Genetic testing discovered the p.M174V mutation in exon 6 of *PSEN2*.

Bibliography

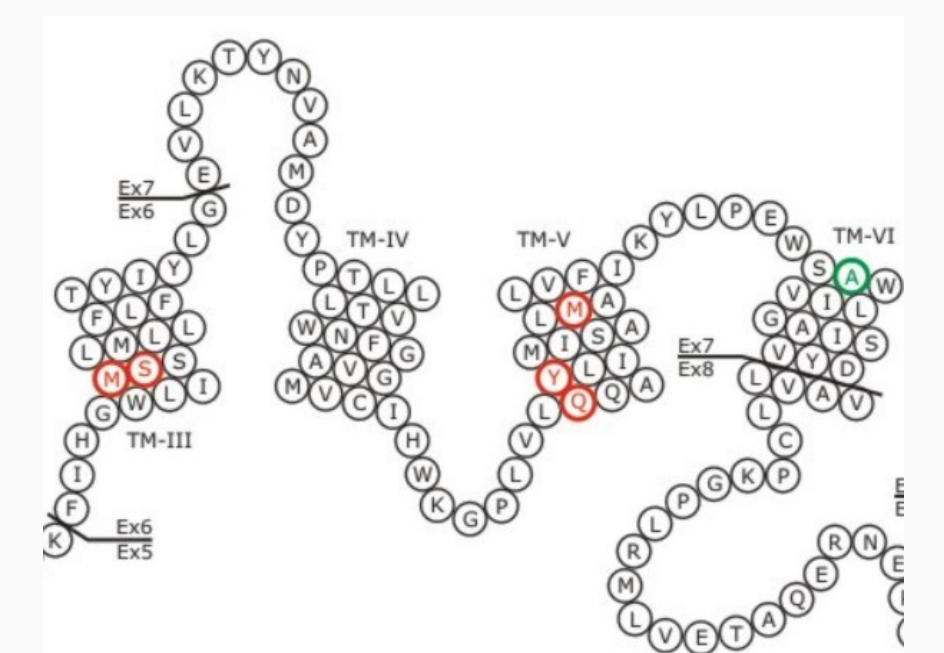
- 1) Alzheimer's disease phenotypes and genotypes associated with mutations in presenilin 2. Jayadev S, Leverenz JB, Steinbart E, et al. *Brain*. 2010 Apr;133(Pt 4):1143-54.
- 2) Genetic screening of Alzheimer's disease genes in Iberian and African samples yields novel mutations in presenilins and APP. Guerreiro RJ, Baquero M, Blesa R, et al. *Neurobiol Aging*. 2010 May;31(5):725-31.
- 3) Increased CSF A β during the very early phase of cerebral A β deposition in mouse models. Maia LF, Kaeser SA, Reichwald J, et al. *EMBO Mol Med*. 2015 May 15;7(7):895-903.

Cerebrospinal fluid biomarker analysis, performed 30 months after onset, revealed levels of t-TAU, p-TAU in the normal range, while beta-amyloid was slightly increased.

Discussion and conclusions

Mutations in *PSEN2* gene are rare and only 22 affected families have been reported in the literature up to now (<http://www.molgen.ua.ac.be>).

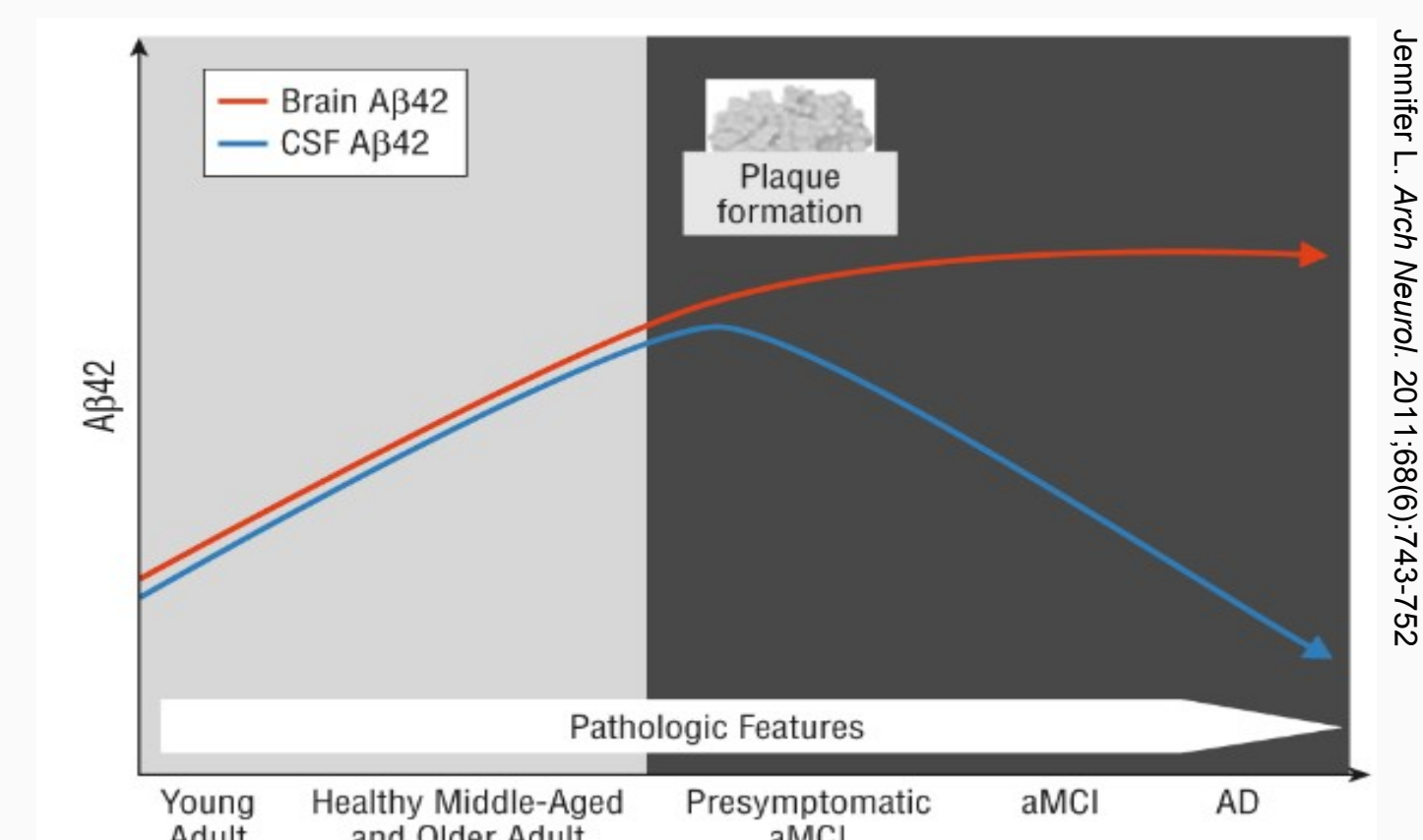
Gene	# Mutations	# Families
<i>APP</i>	42 (9.40 %)	103 (6.92 %)
<i>PSEN1</i>	199 (44.52 %)	427 (28.70 %)
<i>PSEN2</i>	13 (2.91 %)	22 (1.48 %)
<i>C9orf72</i>	1 (0.22 %)	336 (22.58 %)
<i>CHMP2B</i>	4 (0.89 %)	5 (0.34 %)
<i>FUS</i>	23 (5.15 %)	49 (3.29 %)
<i>GRN</i>	69 (15.44 %)	232 (15.59 %)
<i>MAPT</i>	44 (9.84 %)	134 (9.01 %)
<i>TARDBP</i>	33 (7.38 %)	131 (8.80 %)
<i>VCP</i>	19 (4.25 %)	49 (3.29 %)
Total	447	1488



Disease onset in *PSEN2* related EOAD ranges from age 40 to 75 yrs, mean duration of disease is 11 yrs [1].

The p.M174V mutation has been previously reported in two families, from the Iberian peninsula [2] and from South Italy [2].

In our pedigree, clinical features, familiar history and the age at onset variability are compatible with *PSEN2*-EOAD. Concerning the index patient, clinical history was also compatible with vascular dementia. CAA is the key features of APP-AD, however their presence seems rarely associated with *PSEN1* or *PSEN2* mutations. However, our patient carries a MTHFR mutation, whose presence could be linked to an increased vascular risk.



Finally, the increase in CSF beta-amyloid, with normal total and pTAU is puzzling, although these findings have been already reported at very early phase of cerebral A-beta deposition, in humans and mouse models [3].