

The motor circuit in essential tremor with and without resting tremor: insights from tractography and connectomics

Maria Eugenia Caligiuri^{1§}, Gennarina Arabia², Fabiana Novellino¹, Rita Nisticò¹, Maria Salsone¹, Gaetano Barbagallo², Angela Lupo², Andrea Cherubini¹, Aldo Quattrone^{1,2}

¹Neuroimaging Unit, Institute of Bioimaging and Molecular Physiology (CNR-IBFM), National Research Council, Catanzaro, Italy.

²Institute of Neurology, University "Magna Graecia", Catanzaro, Italy.

Introduction

- Essential tremor (ET) has been traditionally described as a mono-symptomatic movement disorder, characterized by postural and action tremor. ET has also recently been associated with resting tremor (rET), which is observed in approximately 19% of patients.
- Cerebello-thalamo-cortical damage has been thoroughly described in the classical presentation of ET, whereas neuroimaging correlates of rET have not yet been clearly identified.
- In this study, we used probabilistic tractography to investigate the structural properties of the motor circuit in essential tremor, with or without resting tremor, and healthy controls, in order to identify regions and pathways that may have a role in determining the different clinical presentation of this disorder.

Materials&Methods

- Twenty-five patients with ET (14 female, mean age 65.1 ± 10.4), 22 patients with rET (10 female, mean age 64.9 ± 13.4) and 25 age- and sex-matched healthy controls underwent the same imaging protocol including whole-brain 3D T1-weighted and diffusion-weighted MRI.
- Motor circuit regions were automatically identified on T1 images: putamen, caudate nucleus, globus pallidus, thalamus, cerebellum, precentral cortex and supplementary motor area (SMA).
- Probabilistic tractography between these nodes was performed on diffusion data in network-mode, in order to reconstruct connections in the motor circuit and to obtain connectivity matrices necessary for computing connectomics measures (nodal and global efficiency).

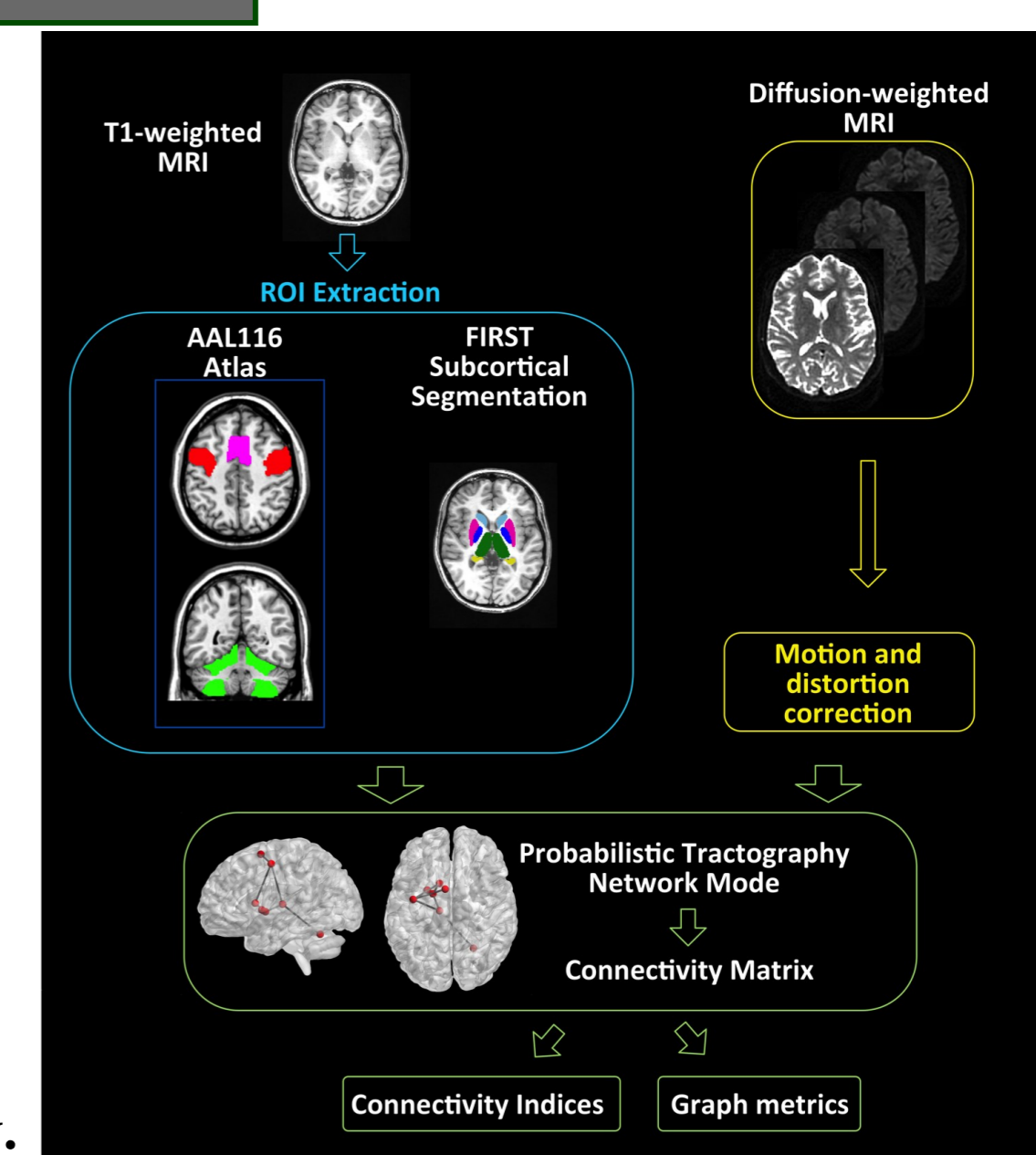


Figure 1. Image processing workflow.

Results

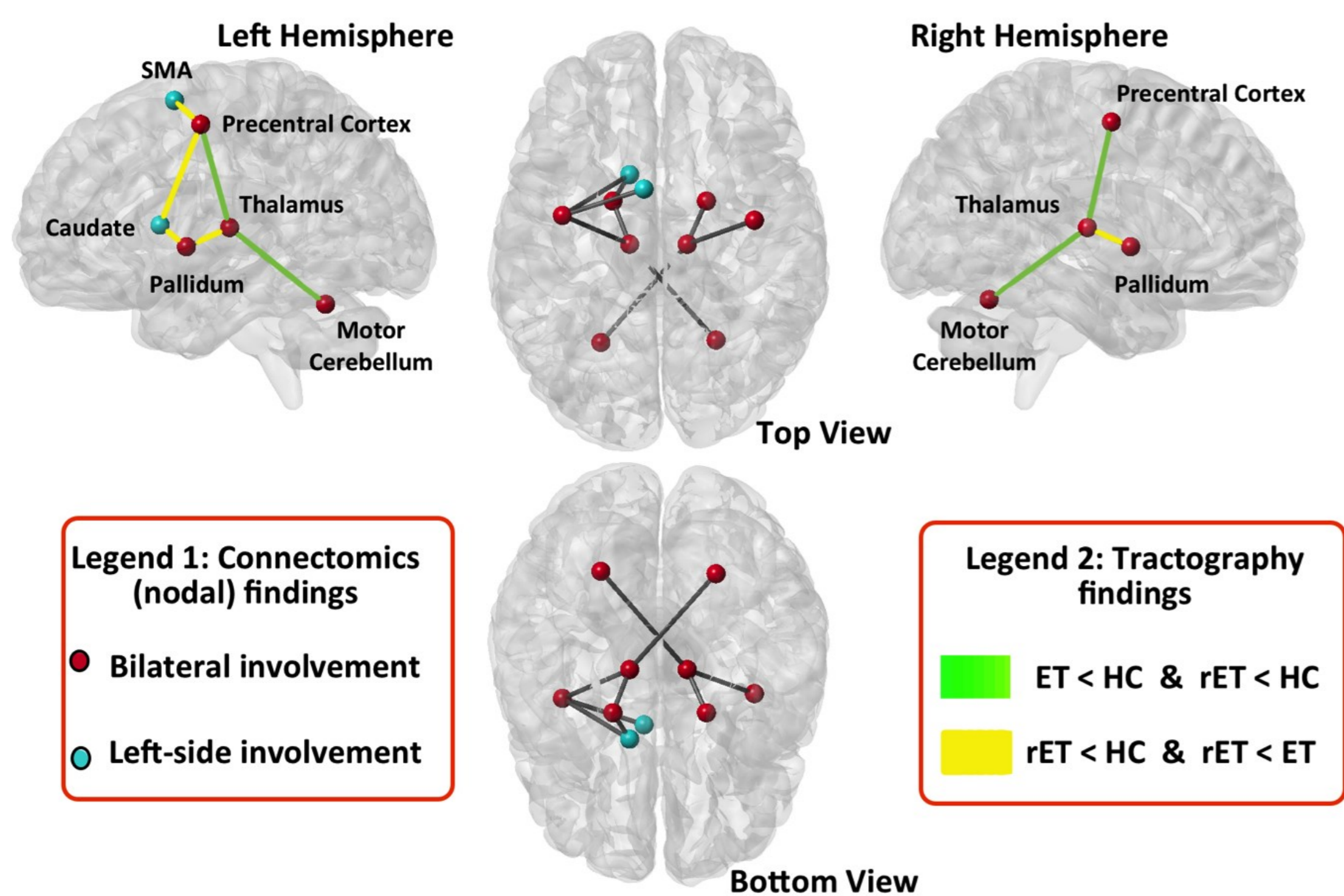


Figure 2. Significant differences in probabilistically reconstructed tracts and connectomics measures

- Compared to healthy controls, patients with essential tremor, regardless of the presence of resting tremor, showed significantly decreased connectivity in the cerebello-thalamo-cortical tract bilaterally.
- Patients with rET, compared to classical ET and healthy controls, showed reduced connectivity in the pallido-thalamic tract bilaterally, and in the left pallido-caudate-precentral-SMA pathway.
- Network analysis revealed increased nodal efficiency of the cerebellum in both groups of patients compared to controls.
- Patients with rET showed increased nodal efficiency in bilateral globus pallidus, left precentral cortex and left caudate compared to patients with ET and controls.
- Thalamic nodal efficiency was increased only in patients with rET compared to controls.

Conclusions

Damage of the pallido-thalamic connection was identified as a possible specific neuroimaging correlate of rET. Moreover, we found evidence of structural alteration of the pathway that connects the cerebellum to the motor cortex, via the thalamus, in all ET patients. Overall, these results suggest that dysfunction of thalamus and globus pallidus may play an important role in determining the different clinical presentations of essential tremor.

References

- Cerasa A and Quattrone A. Linking Essential Tremor to the Cerebellum—Neuroimaging Evidence. *The Cerebellum*, 2015, 1-13.
- Buijink AWG, van der Stouwe MAM, Broersma M, et al. Motor network disruption in essential tremor: a functional and effective connectivity study. *Brain*, 2015, 138(10):2934-2947.
- Novellino F, Nicoletti G, Cherubini A, et al. Cerebellar involvement in essential tremor with and without resting tremor: A Diffusion Tensor Imaging study. *Parkinsonism & related disorders*, 2016.

§ Maria Eugenia Caligiuri, PhD
Institute of Molecular Bioimaging and Physiology (IBFM-CNR)
Neuroimaging Unit of Germaneto (CZ)

Institute of Neurological Sciences
University "Magna Graecia" of Catanzaro

Campus Universitario "S.Venuta"
Viale Europa
88100 Catanzaro

e-mail: me.caligiuri@unicz.it