

# Hemidiaphragmatic paralysis as an unusual manifestation in facioscapulohumeral muscular dystrophy: a case report

Vincenzo Di Stefano<sup>1</sup>, M. Vitale<sup>1</sup>, C. Ferrante<sup>1</sup>, F. Barbone<sup>1</sup>, R. Telese<sup>1</sup>, L. Mancinelli<sup>1</sup>, R. Di Giacomo<sup>1</sup>, R. Tupler<sup>2</sup>, M. Onofri<sup>1</sup>, A. Di Muzio<sup>1</sup>.

<sup>1</sup>Center for Neuromuscular Disease, University "G. d'Annunzio", Chieti, Italy; <sup>2</sup>Department of Biomedical Sciences, University of Modena and Reggio Emilia, Modena, Italy.

**Objective:** to present a case of hemidiaphragm paralysis as an unusual condition in a patient affected by facioscapulohumeral muscular dystrophy (FSHD)<sup>1</sup> and focalize attention about the role of D4Z4 repeat.

**Case report:** a 70 year-old woman, affected by FSHD, was admitted in our hospital. Her father had a not specified muscular disorder and her medical history mentioned hypertension, obesity, recurrent bronchitis, depression and slipped disk (L5-S1) surgically treated.

At the age of 20 she had developed muscle weakness, affecting initially face (with inability to whistle and puffing cheeks), shoulder and arms, followed by lower extremities. Thirty years later she developed difficulties in walking, left foot drop, facial diplegia and scapular winging.

**FSHD clinical score was 13/15.**

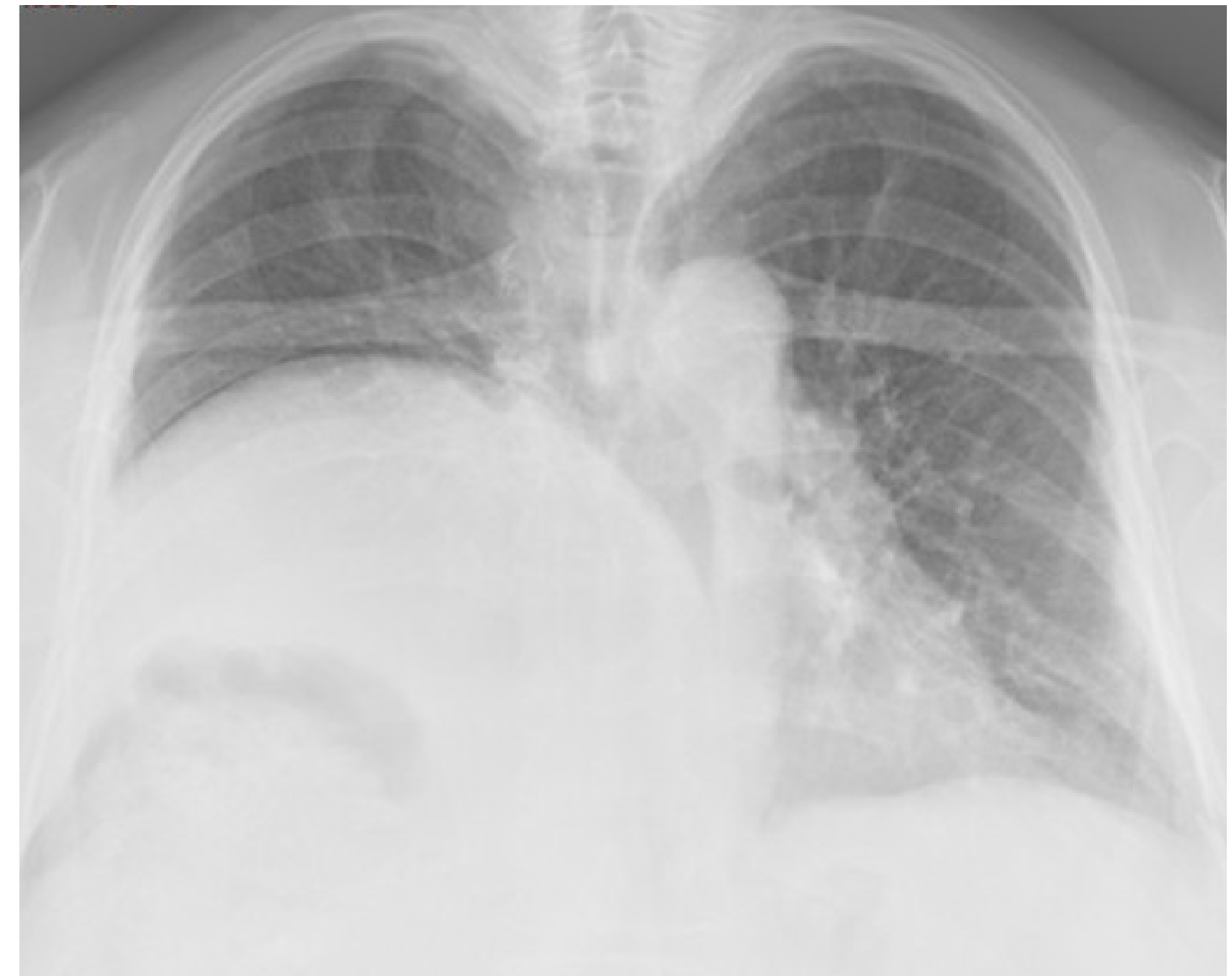Creatine kinase level was normal.

Biceps brachial muscular biopsy showed *variability in fiber size, internal nuclei, increased connective tissue.*

Genetic test for FSHD showed a **D4Z4 fragment of 35 kb (8 units).**

On admission she presented dyspnea and morning headache. Her clinical examination revealed *pectus excavatum and kyphosis, atrophy and muscle weakness of arms and legs, with asymmetric facial weakness, inability to abduct arms, ability to walk with support and steppage gait, positive Beevor's sign.*

A chest X-ray revealed **right hemidiaphragm elevation.**



Right hemidiaphragm elevation in our patient

## Results

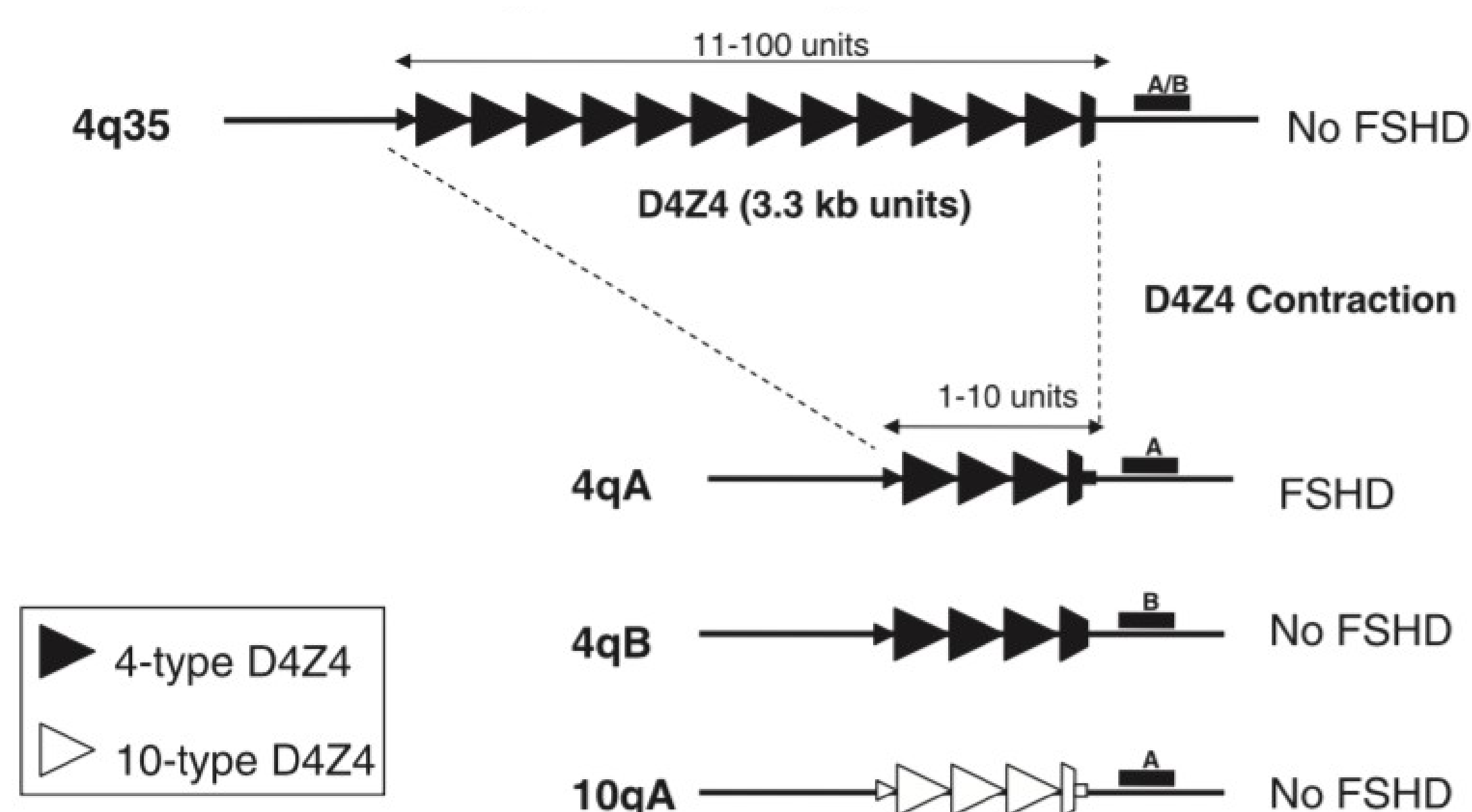
Spirometry showed a restrictive respiratory insufficiency. Nocturnal oximetry demonstrated 17 desaturations (minimum SpO<sub>2</sub> 83%). To relieve her breathing difficulties she used non-invasive positive pressure ventilation (NIPPV) during the night and she slept better and experienced more energy during daily activities. Nocturnal oximetry improved (only 3 desaturations, SpO<sub>2</sub> 89%). The Pompe Disease Dried Blood Spot (DBS) Testing was 45 nM/h (normal 43-200).

## Discussion and conclusion

In a recent study,<sup>2</sup> 3% of healthy subjects from the general population carries a D4Z4 allele with 4-8 units. Usually, when affected, patients carrying this D4Z4 size have a mild phenotype.

To our knowledge only one FSHD patient (5 units) with diaphragm paralysis was reported<sup>3</sup>. He presented severe dyspnea with nocturnal hypoventilation and he was treated successfully with NIPPV.

Respiratory involvement is a very rare condition in FSHD, especially asymmetric diaphragmatic paralysis. In these cases other causes, such as phrenic nerve palsy, must be attempted.



## References

<sup>1</sup>Padberg GW, Lunt PW, Koch M and Fardeau M. "Diagnostic criteria for Facioscapulohumeral Dystrophy". *Neuromuscular Disorders* 1 (1991): 231-234;

<sup>2</sup>Scionti I, Greco F, Ricci G, Govi M, Arashiro P, Vercelli L, Berardinelli A, Angelini C, Antonini G, Cao M, Di Muzio A, Moggio M, Morandi L, Ricci E, Rodolico C, Ruggiero L, Santoro L, Siciliano G, Tomelleri G, Trevisan CP, Galluzzi G, Wright W, Zatz M, Tupier R. "Large-scale population analysis challenges the current criteria for the molecular diagnosis of facioscapulohumeral muscular dystrophy". *Am J Hum Genet.* 2012 Apr 6; 90(4): 628-35;

<sup>3</sup>Hazenbergh A, van Alfen N, Voet NBM, Kerstjens HAM, Wijkstra PJ. "Facioscapulohumeral muscular dystrophy and respiratory failure; what about the diaphragm?". *University of Groningen, The Netherlands. Respiratory Medicine Case Reports* 14 (2015): 37-39.