

BACKGROUND

Glucocorticoids (GC), such as prednisone or deflazacort, are the "gold standard" in Duchenne muscular dystrophy (DMD) treatment, being able to delay the progressive loss of muscle strength and function (1). DMD patients experience secondary osteoporosis with high fracture rate due to immobilization and GC use and up to a third of them are affected by pathologic fractures of both long bones and vertebrae (2). Fractures have a significant impact on mobility and quality of life of patients and vertebral fractures may lead to severe pain and worsening of respiratory function.

Treatments for DMD-related osteoporosis have not been widely explored. Therapy with bisphosphonate alendronate prevented further decrease in bone mineral density over a two-year period (3).

Teriparatide is the biologically active, recombinant N-terminal 1-34 amino acid polypeptide of naturally occurring human parathormone (PTH). It has been approved as the only anabolic therapy for treating patients with osteoporosis who are at high risk for future fracture (3). Teriparatide is an anabolic agent enhancing more the osteoblast-derived bone formation than the osteoclast-derived bone resorption, with a resultant net increase in bone mass (3). Post-menopausal and GC-induced osteoporosis represents the actual approved conditions for its use in humans.

It was previously observed that the administration of black bear parathyroid hormone was associated to improvement of bone mass in the dystrophin-deficient mdx mouse (4). To date, the effects of teriparatide in human subjects suffering from DMD related osteoporosis has not been reported.

MEDICAL HISTORY

- The patient came to our observation at 20 years of age
- He had a duplication of exon 12 of *DYS* gene
- He was wheelchair bound since the age of 9 years
- He had GC treatment from 8 to 12 years of age and from 18 to 20 years of age
- He was on Vit. D and Ca supplementation since 16 years of age
- He had severe scoliosis with lumbar vertebrae rotation (Fig.1)
- On RX we identified three severe (grade 3) vertebral fractures defined by morphometric examination, in accordance to Genant's classification (Fig.1).
- Back pain at baseline (VAS 9)

MATERIALS AND METHODS

- Visit time points: baseline, 6, 12 and 18 months
- Laboratory analysis: Serum CTX, BGP, ALP, bone ALP, Ca, PTH, vit.D3, creatinine, AST, ALT, GGT, and CBC; calciuria, creatinuria, sclerostin
- ECG
- VAS every 3 months; SF36 at baseline and 18 months
- DXA at lumbar spine (L1-L4) at baseline, 12 and 18 months
- Spine X-ray
- Subcutaneous injection of teriparatide 20µg/day
- Calcifediol supplementation (100 µg/weekly)

RESULTS

Although, in accordance to Italian guidelines, subjects may be treated with teriparatide up to 24 months, we report preliminary data after 18 months of treatment.

Safety

- Teriparatide was well tolerated and adverse events have not been reported.
- Cardiovascular safety was investigated and no ECG abnormalities were detected during the observation period.

Efficacy after 18 months

- Z-score value showed a relevant increase (+18%) (Fig. 2), and no additional clinical and/or morphometric vertebral fractures were detected.
- We observed an early noticeable increase (after 6 months) of bone formation markers, in particular BGP, which was maintained over 18 months, without relevant changes of CTX levels (Table 1). These findings highlight the anabolic effect of teriparatide in this time frame.
- Unexpectedly, we observed increased sclerostin serum levels. Sclerostin is an inhibitor of the Wnt-signaling pathway (Table 1),
- We noted a QoL improvement demonstrated by SF-36 composite (PCS and MCS) and domain scores increment (Fig. 3).
- Moreover, teriparatide significantly reduced back pain intensity after 3 months (VAS 3), with disappearance of pain at 6 months (VAS 0). (Fig. 4)

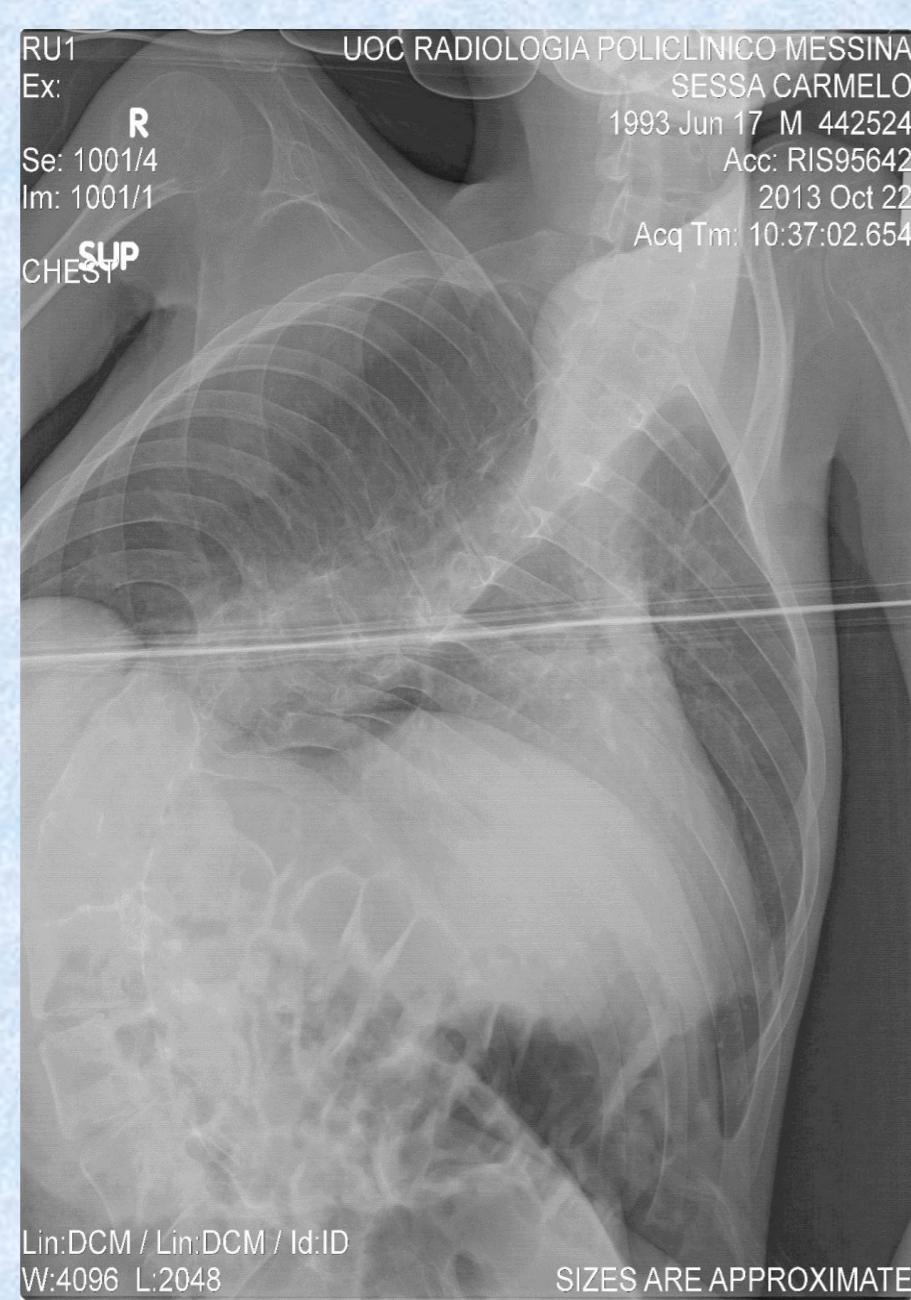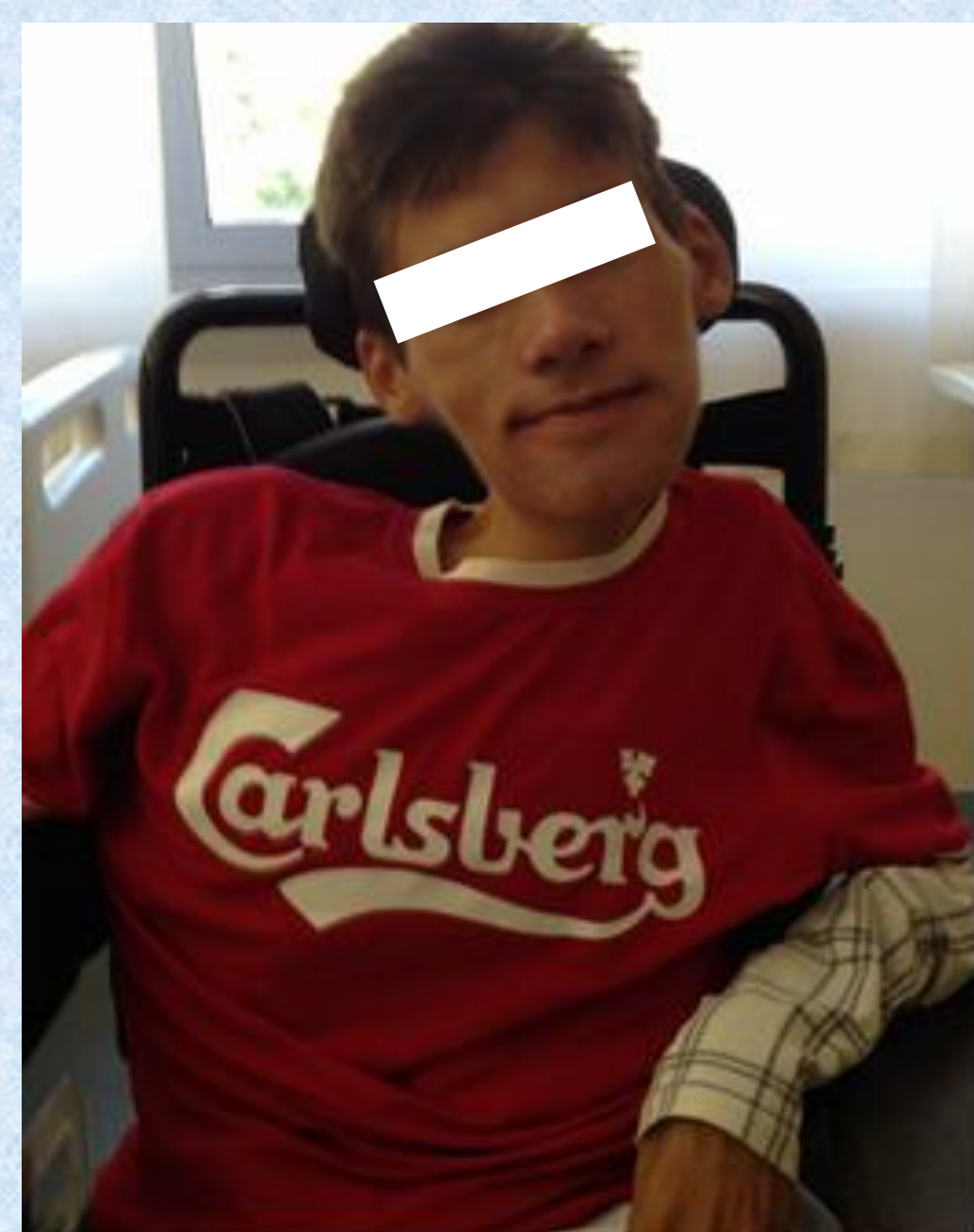


Fig.1

	Baseline	6 months	12 months	18 months
CTX (ng/ml)	0.8	0.7	0.9	1.1
BGP (ng/ml)	14.3	102	94	76
Bone ALP (mg/dl)	18.1	25.5	50.45	48.2
Ca (mg/dl)	9.4	9.1	9.2	9.8
Vit. D3 (ng/ml)	32.2	36.8	44.1	39.4
Sclerostin (pmol/l)	30.4	46.4	-	-

Table 1: BIOCHEMISTRY

Baseline					
Regione	Area (cm ²)	BMC (g)	BMD (g/cm ²)	T-score	Z-score
L1	16.95	6.48	0.382	-6.3	-6.3
L2	15.76	5.76	0.365	-6.6	-6.6
L3	14.39	5.00	0.348	-6.9	-6.9
L4	14.50	4.42	0.305	-7.1	-7.1
Totale	61.60	21.66	0.352	-6.7	-6.7

12 months					
Regione	Area (cm ²)	BMC (g)	BMD (g/cm ²)	T-score	Z-score
L1	14.57	6.65	0.456	-5.6	-5.6
L2	13.64	5.80	0.425	-6.1	-6.1
L3	15.27	6.94	0.455	-5.9	-5.9
L4	15.42	6.03	0.391	-6.4	-6.4
Totale	58.90	25.43	0.432	-6.0	-6.0

18 months					
Regione	Area (cm ²)	BMC (g)	BMD (g/cm ²)	T-score	Z-score
L1	14.63	7.33	0.501	-5.2	-5.2
L2	13.91	6.70	0.482	-5.6	-5.6
L3	15.16	7.25	0.479	-5.7	-5.7
L4	14.61	6.43	0.440	-5.9	-5.9
Totale	58.31	27.71	0.475	-5.6	-5.6

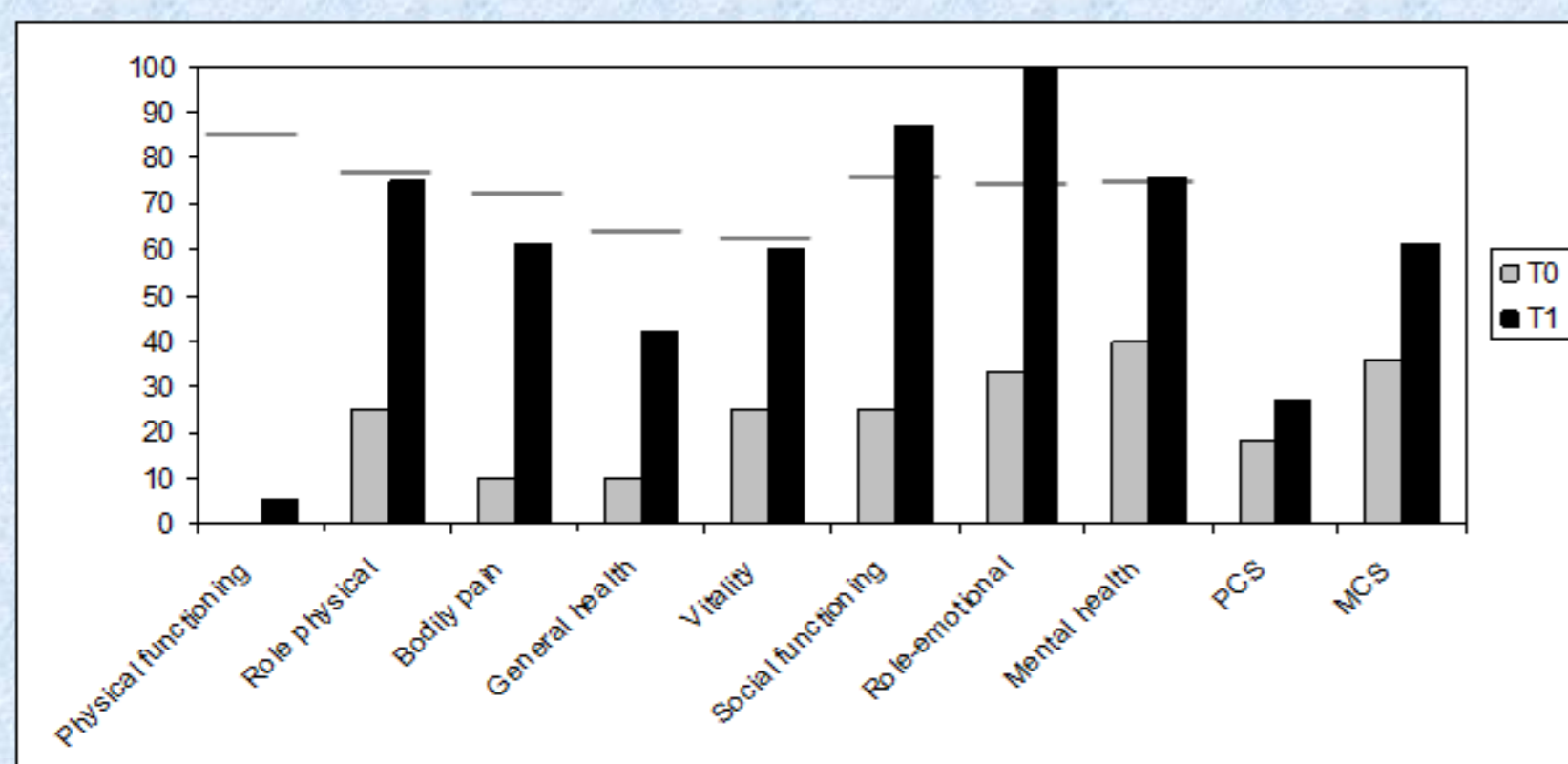


Fig.3: SF-36 domains results before (T0) and after 18 months (T1) of treatment

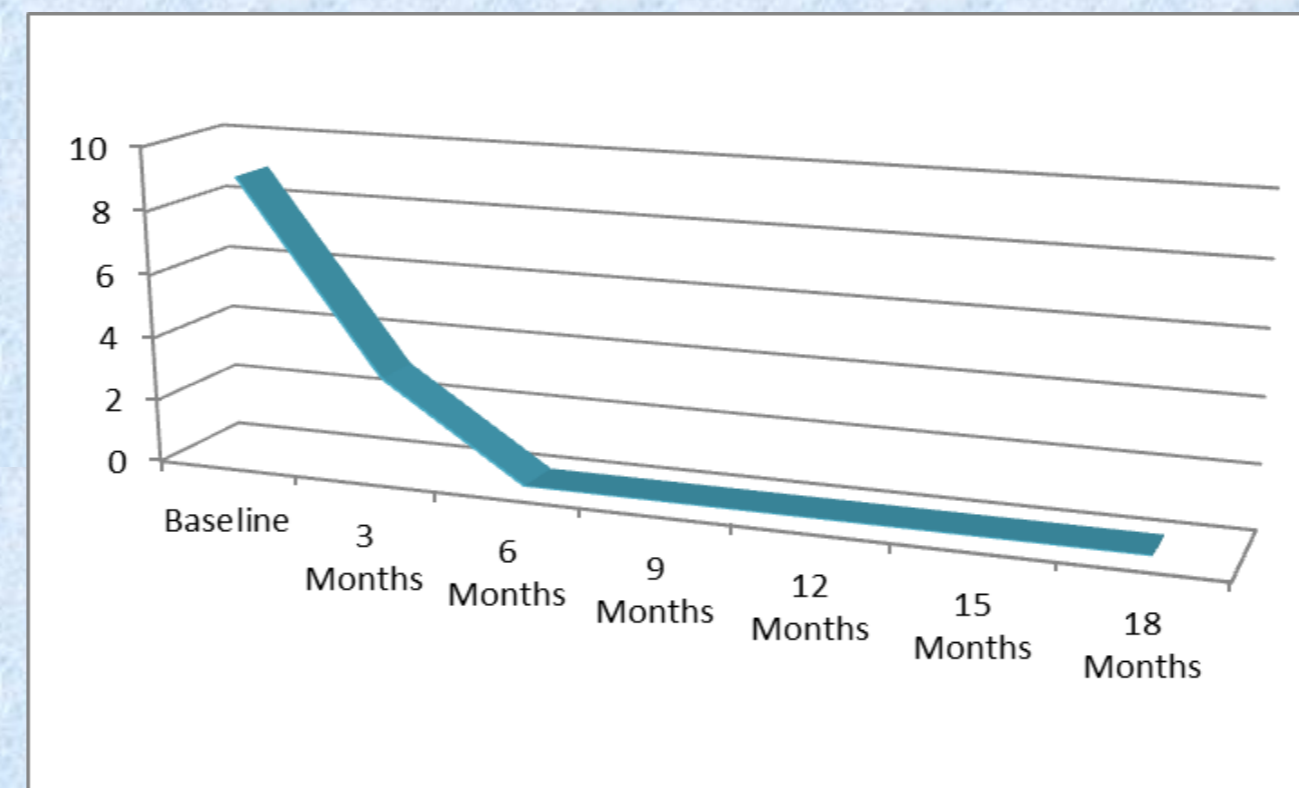


Fig.4: VAS

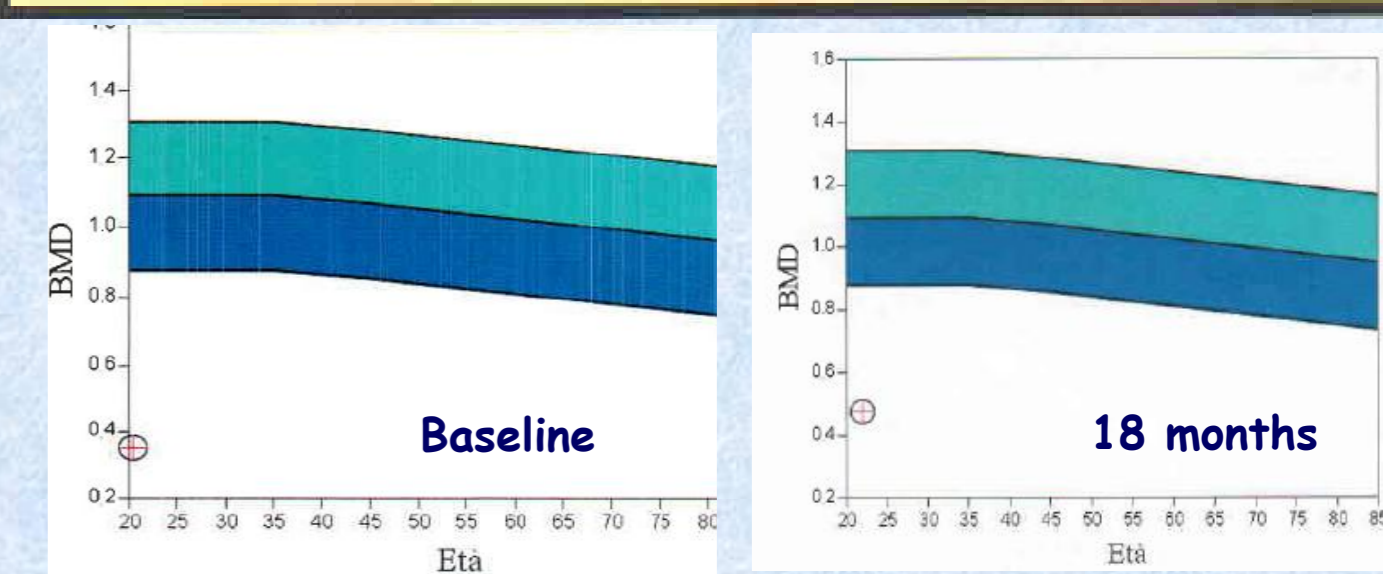


Fig.2 : DXA AT LUMBAR SPINE (L1-L4)

CONCLUSIONS

- To our knowledge, this is the first report in which teriparatide was administered to a young adult with DMD.
- Unexpectedly, we observed increased sclerostin serum levels. Sclerostin is an inhibitor of the Wnt-signaling pathway, expressed almost exclusively in the osteocytes, and this signaling plays an important role in the regulation of proliferation and differentiation of osteoblast precursor cells. We hypothesize that increased sclerostin may have been related to the increase in the number of osteocytes and the concomitant absence of mechanical load.
- Considerably, teriparatide has been previously associated to reduction of back pain in subjects treated for severe osteoporosis. Our patient reported no back pain early after treatment and this reflected in a considerable improvement in his quality of life, including aspects related to social functioning and mental and emotional status.
- Because of improved life expectancy in DMD patients, preventing osteoporosis, but also managing related fractures and pain, should be considered a relevant therapeutic goal and teriparatide might be a promising treatment for DMD related osteoporosis to be tested in a large cohort.

REFERENCES

1. Novel approaches to corticosteroid treatment in Duchenne muscular dystrophy. Hoffman EP1, Reeves E, Damsker J, Nagaraju K, McCall JM, Connor EM, Bushby K. *Phys Med Rehabil Clin N Am.* 2012 Nov;23(4):821-8. doi: 10.1016/j.pmr.2012.08.003.
2. Mechanisms inducing low bone density in Duchenne muscular dystrophy in mice and humans. Rufo A1, Del Fattore A, Capulli M, Carvello F, De Pasquale L, Ferrari S, Pierroz D, Morandi L, De Simone M, Rucci N, Bertini E, Bianchi ML, De Benedetti F, Teti A. *J Bone Miner Res.* 2011 Aug;26(8):1891-903. doi: 10.1002/jbmr.410.
3. Teriparatide or alendronate in glucocorticoid-induced osteoporosis. Saag KG1, Shane E, Boonen S, Marín F, Donley DW, Taylor KA, Dalsky GP, Marcus R. *N Engl J Med.* 2007 Nov 15;357(20):2028-39.
4. Black bear parathyroid hormone has greater anabolic effects on trabecular bone in dystrophin-deficient mice than in wild type mice. Gray SK1, McGee-Lawrence ME, Sanders JL, Condon KW, Tsai CJ, Donahue SW. *Bone.* 2012 Sep;51(3):578-85. doi: 10.1016/j.bone.2012.05.003.