



E. Filippelli¹, G. Annesi², S. Barone¹, M. Gagliardi², A. Granata¹, G. Iannello², S. Polidoro¹, S. Scannapieco¹, T. Tallarico¹, R. Nisticò³, P. Valentino¹, A. Quattrone¹⁻³.

¹ Institute of Neurology, University "Magna Graecia", Germaneto (CZ), Italy

² Institute of Molecular Bioimaging and Physiology, National Research Council, Catanzaro, Italy

³ Neuroimaging Research Unit, National Research Council, Catanzaro, Italy

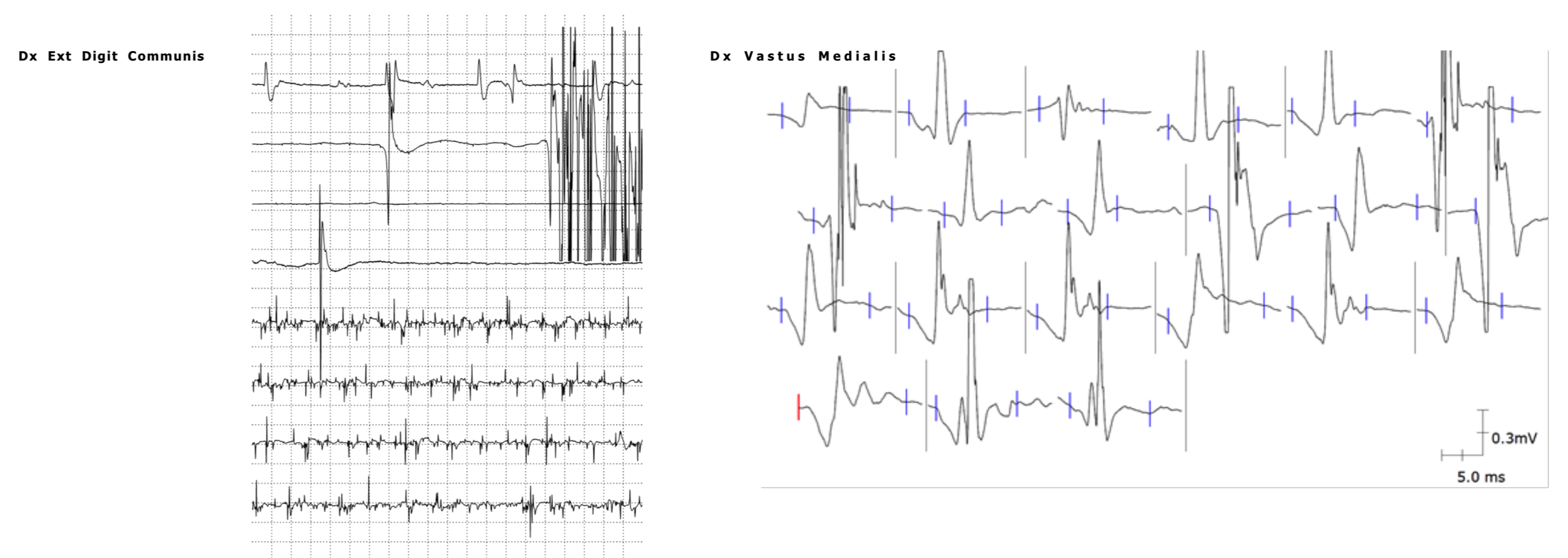
Introduction

Camptocormia is a gait disorder characterized by severe forward flexion of the thoracolumbar spine linked to a variety of neurological conditions; it's occasionally observed in ALS patients and when present, it's usually evident late in the course of the illness. Mutations in the TARDBP gene, encoding TAR DNA binding protein (TDP) 43, were detected in 1% of ALS patients (both familial and sporadic ALS cases), suggesting that such mutations may be linked to ALS pathogenesis.

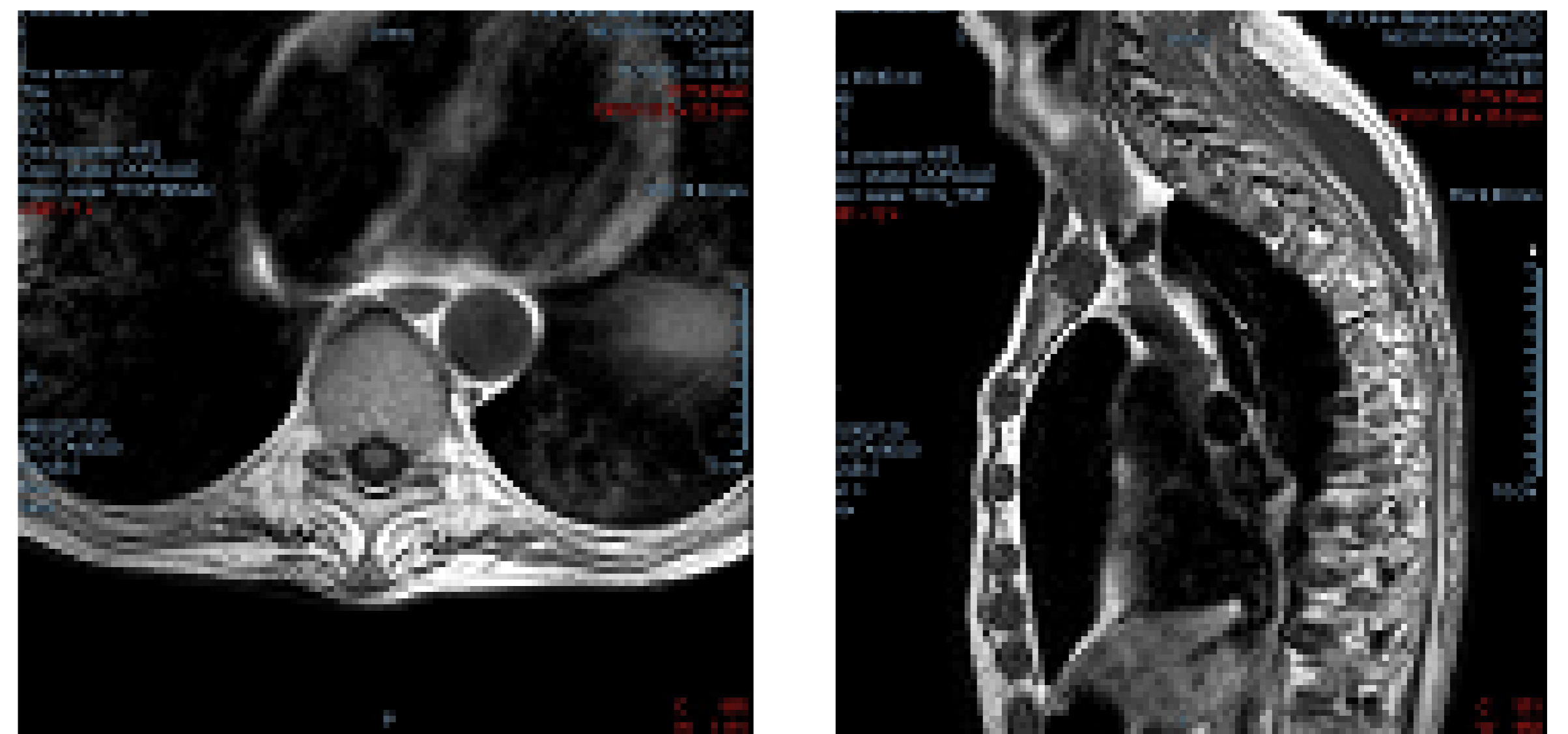
Case report

A 66-year-old patient presented with an one year history of camptocormia and weight loss; the deep tendon reflexes exam showed hyporeflexia to limbs. The patient was cognitively unimpaired. Laboratory investigations, motor evoked potentials, cranial, cervical, dorsal and lumbar MRI were normal. He was underwent to electromyography examination that demonstrated marked active denervation at rest in all four limbs, in trapezius and paravertebral dorsal muscles and polyphasic motor unit potentials with long duration and high amplitude on voluntary contraction; a diagnosis of "Lower Motor Neuron Disease" was made according to El Escorial revised criteria. Genomic DNA was extracted from peripheral blood by standard method. The purified polymerase chain reaction products were sequenced on exon 6 of TARDBP gene using an ABI 3500 Genetic Analyzed. We identified the mutation c.800A>G (p.Asn267Ser) in TARDBP gene in heterozygous state. This mutation was not found in a control population of 300 healthy individuals. Sixteen months after the onset, the patient developed a respiratory failure that rapidly worsened. He died a few weeks later of acute respiratory distress. No upper motor neuron signs never appeared.

EMG



RMN RACHIDE DORSALE



Discussion & Conclusions

Our patient is the first case described of camptocormia as type of onset of lower motor neuron disease associated with a mutation in TARDBP gene. It regards a severe phenotype of lower motor neuron disease, because the patient died in a short period for an acute respiratory failure and upper motor neuron signs never appeared. So, we suggests to verify the diagnostic hypothesis of motor neuron disease in the patient who presents camptocormia; furthermore, it would be useful to perform the genetic analysis in order to show the presence of TARDBP gene mutations and to produce additional evidence of a possible association with this specific mutation and the atypical and severe phenotype that has been described in this report.

References:

1. Finsterer J1, Strobl W: Presentation, etiology, diagnosis, and management of camptocormia. *Eur Neurol.* 2010;64(1):1-8. doi: 10.1159/000314897. Epub 2010 Jun 8.
2. Feriha O1, Aytul M, Hasan M: A case of camptocormia (bent spine) secondary to early motor neuron disease. *Behav Neurol.* 2004;15(1-2):51-4.
3. Kirby J1, Goodall EF, Smith W, Highley JR, Masanzu R, Hartley JA, Hibberd R, Hollinger HC, Wharton SB, Morrison KE, Ince PG, McDermott CJ, Shaw PJ: Broad clinical phenotypes associated with TAR-DNA binding protein (TARDBP) mutations in amyotrophic lateral sclerosis. *Neurogenetics.* 2010 May;11(2):217-25. doi: 10.1007/s10048-009-0218-9. Epub 2009 Sep 17.
4. Corrado L1, Ratti A, Gellera C, Buratti E, Castellotti B, Carlomagno Y, Ticozzi N, Mazzini L, Testa L, Taroni F, Baralle FE, Silani V, D'Alfonso S: High frequency of TARDBP gene mutations in Italian patients with amyotrophic lateral sclerosis. *Hum Mutat.* 2009 Apr;30(4):688-94. doi: 10.1002/humu.20950.

