

ACUTE ONSET MOVEMENT DISORDER AND AUTOIMMUNE NEUROLOGICAL SYNDROMES: A CASE SERIES

E Innocenti, S Gallerini, L Marsili, M Bartalucci, C Marotti, C Scarpini, K Plewnia, R Marconi

Unit of Neurology, Misericordia Hospital, Grosseto, Italy

Objective

Acute onset movement disorders (MDs) are a heterogeneous group of diseases that can occur as a postinfectious, paraneoplastic or idiopathic process often associated to autoimmune syndromes of central nervous system (CNS). MDs have been associated with a variety of autoimmune diseases, including chorea, pediatric neuropsychiatric disorders, gluten sensitivity, systemic lupus erythematosus, antiphospholipid syndrome, paraneoplastic and other autoimmune encephalopathies. Acute onset MDs usually show a rapidly progressive disease evolution. The clinical features are extremely variable, ranging from cognitive or psychiatric symptoms and seizures to MDs. Both hyperkinetic and hypokinetic (tremors, dystonia, chorea, ballism, myoclonus, parkinsonism and ataxia) acute onset MDs are described. Although antibodies anti-CNS-antigens have been identified, the pathogenesis of these autoimmune movement disorders is unclear.

Materials and Methods

We describe ten patients admitted to our institution from Jan 2013 to May 2016 with complex MDs or neuropsychiatric syndromes and an acute or subacute onset. An extensive diagnostic program was done to exclude other secondary causes (e. g. stroke, primary brain tumor, infectious diseases). It included routine blood exams, brain and spinal MRI, EEG, neurophysiological studies, CSF examination, chest, abdomen and pelvis CT and PET to reveal associated tumors, detection of antineuronal antibodies. Finally an alternative diagnosis was excluded and an autoimmune basis was considered.

Results

All the included patients were treated with corticosteroids or intravenous immunoglobulin with improvement in six of them (60%). Three patients showed a poor outcome, and one patient experienced a mild improvement in the acute phase, but he died 6 months later because of his cancer.

Discussion and Conclusions

It is important to keep in mind that acute onset MDs with or without any other symptom associated (e. g. cognitive or psychiatric) might have an autoimmune basis. In this view, we suggest that in suspected paraneoplastic syndromes the goal is to search for a hidden tumor. In other acute neurological syndromes the aim is the early diagnosis of a possible immune-mediated nervous system disease and to start as soon as possible an immunosuppressive therapy.

Table	Intracellular vs cell surface antigens		
	Intracellular, onconeural antigen	Intracellular, synaptic antigen	Cell surface or synaptic receptor
Antigens	Hu, CRMP5, Ri, Yo, Ma2	GAD, amphiphysin	NMDAR, AMPAR, GABA(B)R, LGI1, Caspr2, GlyR
Age	Predominantly older individuals	Usually adults	All ages, some syndromes predominate in children
Tumor association	Yes	Varies with antigen	Varies with antigen and age: GABA(B) R>AMPA>Caspr2>NMDAR>LGI1>GlyR
Function of the antigen	Unclear for many antigens	Known	Known
Relation syndrome-antigen function	No	Yes	Yes
Main pathogenic mechanism	Cytotoxic T-cells, antibodies (?)	Cytotoxic T-cells and antibodies	Antibodies
Response to treatment	Only 10%-30% had mild response	Only ~60% have partial improvement	Substantial or full recoveries in ~75%-80%
Relapses	Infrequent (usually monophasic and irreversible)	Infrequent (symptoms may fluctuate)	Varies with antigen (10%-25%)

Rosenfeld et al., 2013

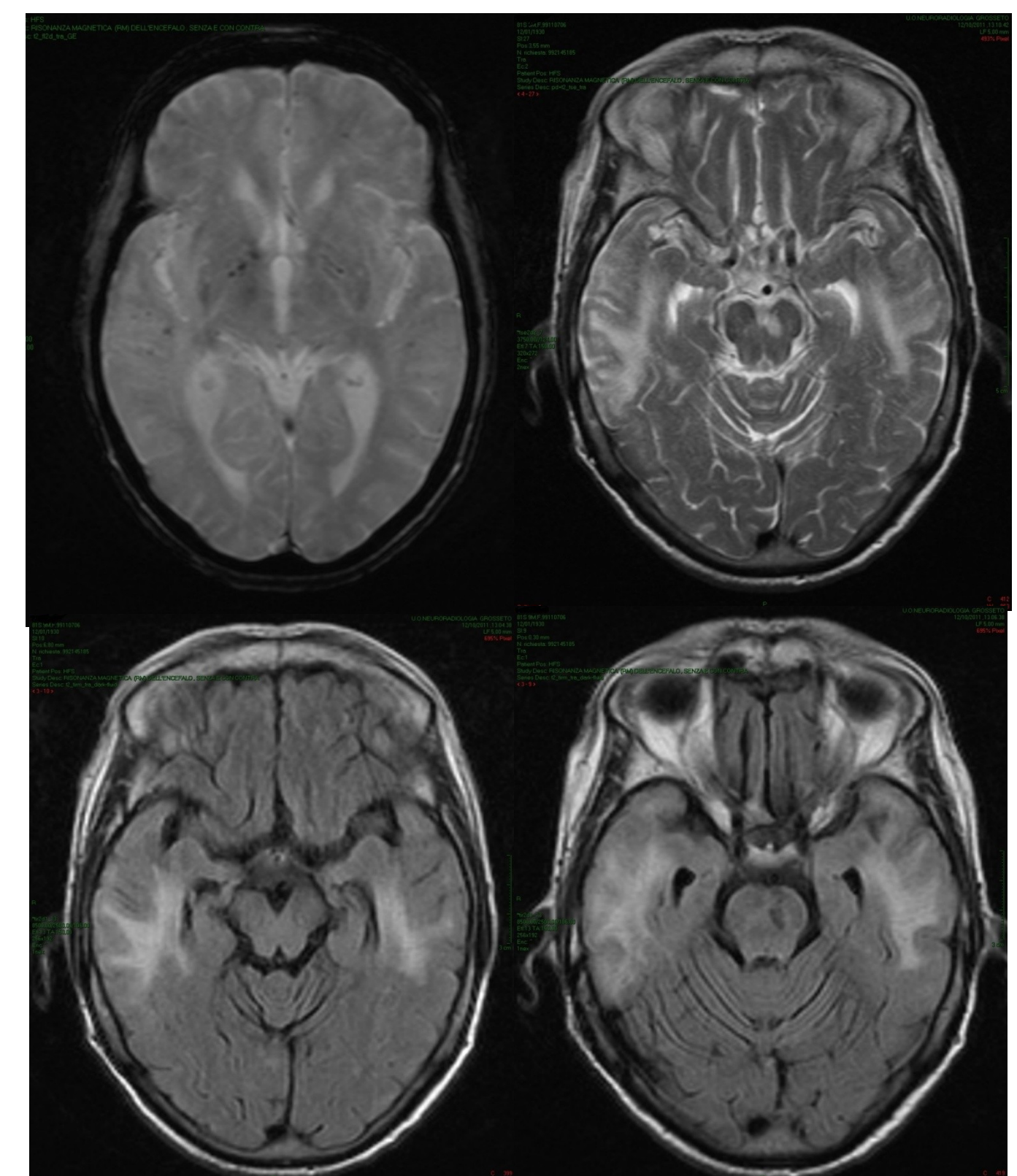


Fig 1: CAA related inflammation: Subcortical, bilateral, asymmetric T2/Flair hyperintensities with mass effect and multiple microbleeds in gradient-echo

Patient	Neurological syndrome	Serum screening	Tumor screening	CSF examination	MRI	Proposed diagnosis	Treatment	Outcome
M, 72	Opsoclonus with myoclonus and ataxia (acute onset)	Onconeural Abs negative	Gastric cancer (after second screening)	Normal	Normal cranial MRI	Paraneoplastic Opsoclonus-Myoclonus-ataxia syndrome	IVig, steroids	Mild improvement, death 6 months later
F, 73	MND	Onconeural Abs positive (YO)	History of Linfooma	Normal	Normal cranial and spinal MRI	Paraneoplastic MND	IVig	Poor Progressive worsening of the symptoms
F, 61	Myoclonus and delirium with ataxia	Onconeural and NS Abs negative (including NMDA) Antithyroid Abs positive (high title)	Negative	Elevated IgG index without specific oligoclonal bands Virus PCR negative	Normal cranial MRI	Hasimoto encefalopathy Limbic encephalitis?	IVig, steroids	Good, total recovery
F, 66	Myoclonus and delirium	Onconeural Abs negative and VGKC-Abs Antithyroid Abs positive	Negative	Not performed	Normal MRI	Hasimoto encefalopathy Limbic encephalitis?	IVig (periodics)	Good
F, 66	Sensitive ataxia and delirium	Onconeural and NS Abs negative; Ganglioside- Abs negative; Serum GAD-Abs positive	Negative	Elevated proteins without IgG index and specific oligoclonal bands Virus PCR negative	Normal cranial and spinal MRI	GAD-ataxia syndrome Limbic encephalitis?	IVig	Poor
F, 81	Tremor and dementia (subacute onset)	Normal Apo E ε4/ ε4	Negative	Normal Virus PCR negative	Subcortical, bilateral, asymmetric T2/Flair hyperintensities with mass effect and multiple microbleeds in gradient-echo	Cerebral amyloid angiopathy - related inflammation	Steroids	Mild
F, 73	Acute ataxia with parkinsonism and dementia	Normal Apo E ε4/ ε4	Negative	Elevated proteins without IgG index and specific oligoclonal bands Virus PCR negative	Subcortical, bilateral, asymmetric T2/Flair hyperintensities with mass effect and multiple microbleeds in gradient-echo	Cerebral amyloid angiopathy - related inflammation	Steroids	Good
F, 58	Myoclonus and delirium	Onconeural and NS Abs negative	Negative	Normal Virus PCR negative	Normal cranial MRI	Limbic encephalitis	IVig	Good
M, 79	Chorea (acute onset)	Antiphospholipid Abs HD negative	Negative	Not performed	Multiple gliotic white matter lesions	Antiphospholipid - related chorea	Steroids, Tetrabenazine	Good
F, 75	Acute onset progressive ataxia (subacute onset)	Onconeural Abs positive (YO)	Tongue cancer (linfooma)	Not performed	Normal MRI	Paraneoplastic cerebellar degeneration	Surgical	No

References

- 1) Dalmau J and Rosenfeld M. Paraneoplastic syndromes of the CNS. Lancet Neurol 2008; 7: 327-40.
- 2) Panzer J, Dalmau J. Movement disorders in paraneoplastic and autoimmune disease. Curr Opin Neurol. 2011.
- 3) Rosenfeld M, Titulaer MJ, Dalmau J. Paraneoplastic syndromes and autoimmune encephalitis: five new things. Neurology Clinical Practice 2012; 2: 215-222