

# RITUXIMAB AS AN EFFECTIVE TREATMENT OPTION AFTER NATALIZUMAB WITHDRAWAL.

S. Malucchi, M. Capobianco, A. di Sapia, M. Io Re, F. Sperli, M. Malentacchi, M. Matta, A. Oggero, A. Bertolotto.

*Neurologia 2-CRESM, University Hospital San Luigi Gonzaga, Orbassano, Turin;*

*SM received speaking honoraria from Biogen, Novartis, Teva, Merck Serono;*

*MC received speaking honoraria/consultant fees from Biogen, Novartis, Teva, Merck Serono,*

*Genzyme and Almirall; AdS received consultant fees from Biogen, Merck Serono; MLR received*

*travel expenses from Biogen, Novartis, Teva; FS, MM, MM and AO received speaking honoaria from*

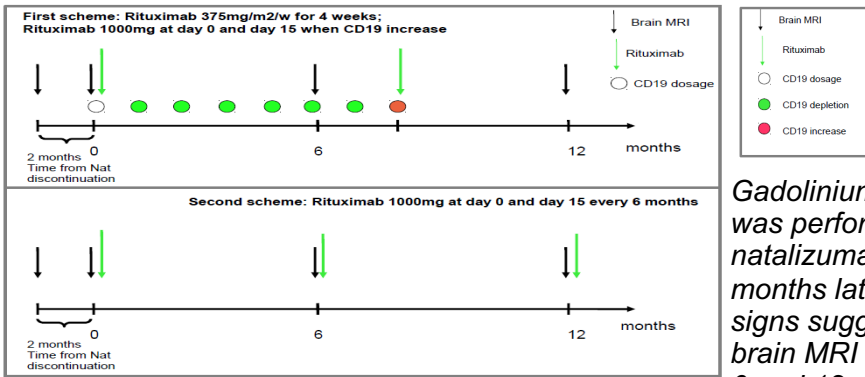
*Biogen; AB received honoraria from Almirall, Bayer, Biogen, Merck Serono, Novartis, Teva, Genzyme.*

## INTRODUCTION

No guidelines about patients management after natalizumab discontinuation exist. In a previous study (Malucchi et al, MSDD 2016,) we presented our experience about the use of rituximab soon after natalizumab withdrawal in 10 patients. Here we describe a larger population treated with rituximab after natalizumab. Aim of this study: to evaluate rituximab efficacy in controlling disease activity after natalizumab discontinuation.

## PATIENTS

29 RR-MS patients stopped natalizumab treatment after a median number of 56 infusions (range 12-100) because of high risk of PML (28 patients had Stratify index >1.5) or convenience (1 patient); switch to rituximab was planned after a wash out period of two months.



*Gadolinium-enhanced brain MRI was performed after the last natalizumab infusion and two months later in order to exclude signs suggestive for PML. Then brain MRI was performed at 6 and 12 months after rituximab infusion*

## RESULTS (Table 1)

N° of patients	29 (22F/7M)
Median n° of natalizumab infusions	56 (12-100)
Median EDSS after last natalizumab infusion	3.0 (1.0-7.0)
Median wash out (months)	2.8 (1.4-7.9)
Patients who relapsed during wash-out	1 *
Patients with radiological activity at 6 months after Rituximab	0
Patients with radiological activity at 12 months after Rituximab	0
Patients who relapsed during Rituximab treatment (follow up 1 year)	0 **

\* this patient had a wash out period of 7.9 months

\*\* 2 patients had exacerbation of paresthesiae without evidence of radiological activity

## CONCLUSIONS

Rituximab represents a valid and effective treatment option after natalizumab discontinuation; rituximab therapy must be started after a short wash out period.