

Post traumatic dissecting pseudoaneurysm of the internal carotid artery: Dr. Jekyll or Mr. Hyde?

L. Poli¹, M.A. Manes¹, D. Mardighian³, N. Gilberti², M. Gamba², A. Morotti¹, P. Costa¹, V. De Giuli¹, F. Caria¹, M. Magoni², R. Gasparotti³, A. Padovani¹, A. Pezzini¹
¹Neurology Unit, University of Brescia (Brescia); ²Vascular Neurology Unit, Spedali Civili (Brescia), ³Neuroradiology Unit, University of Brescia (Brescia)

Background

Carotid artery dissection can lead to the development of arterial dilations, known as dissecting pseudoaneurysms. These lesions have usually a benign natural history, remaining clinically silent and stable on imaging follow-up.

Case description

A 35-year-old male was admitted to the Emergency Department because of major head trauma. Brain CT showed acute subdural hematoma and right temporal pole parenchymal hemorrhages.

After extubation and sedation withdrawal, the neurological examination showed the presence of left Villaret Syndrome (deficit of the IX-X-XI-XII cranial nerves and Horner's sign). Brain MRA identified the presence of left extracranial internal carotid artery dissection along with a dissecting pseudoaneurysm compressing the lower 4 cranial nerves and sympathetic fibers and 80% lumen stenosis. After complete resolution of the intracranial bleeding, antiplatelet treatment was started.

Six months later the patient experienced acute onset non fluent aphasia (NIHSS: 4) with normal CT scan and received systemic thrombolysis. Brain MRI showed the presence of acute insular and occipital left ischemic lesions, likely of embolic etiology. Vessel imaging detected the presence of a rounded mass with concentric laminated rings and heterogeneous signal intensity within the known pseudoaneurysm, highly suggestive of thrombosis at various stages of evolution. To prevent further embolization, the patient underwent endovascular treatment of the pseudoaneurysm with a flow-diverter device, followed by dual antiplatelet treatment. The procedure was well tolerated and the patient was discharged with a normal examination.

Discussion

Dissection of the carotid and vertebral arteries can result in the development of aneurysmal dilations at the site of dissection, known as dissecting pseudoaneurysms. Dissections through the subadventitial layer may result in aneurysmal dilatation that can lead to late embolic complications, nerve compression, or rupture. The incidence of dissections resulting in pseudoaneurysm formation has been reported to range from 5% to 40%.

The natural history of this condition is a benign one. Indeed, dissecting pseudoaneurysms usually remain clinically silent and stable on imaging follow-up. There is no accepted consensus on the optimal management of dissecting pseudoaneurysms. Clinicians should be aware of the possible unfavourable evolution of dissecting pseudoaneurysms, in order to provide strict clinical and imaging follow-up and prompt recognition and treatment in case of vascular complications.

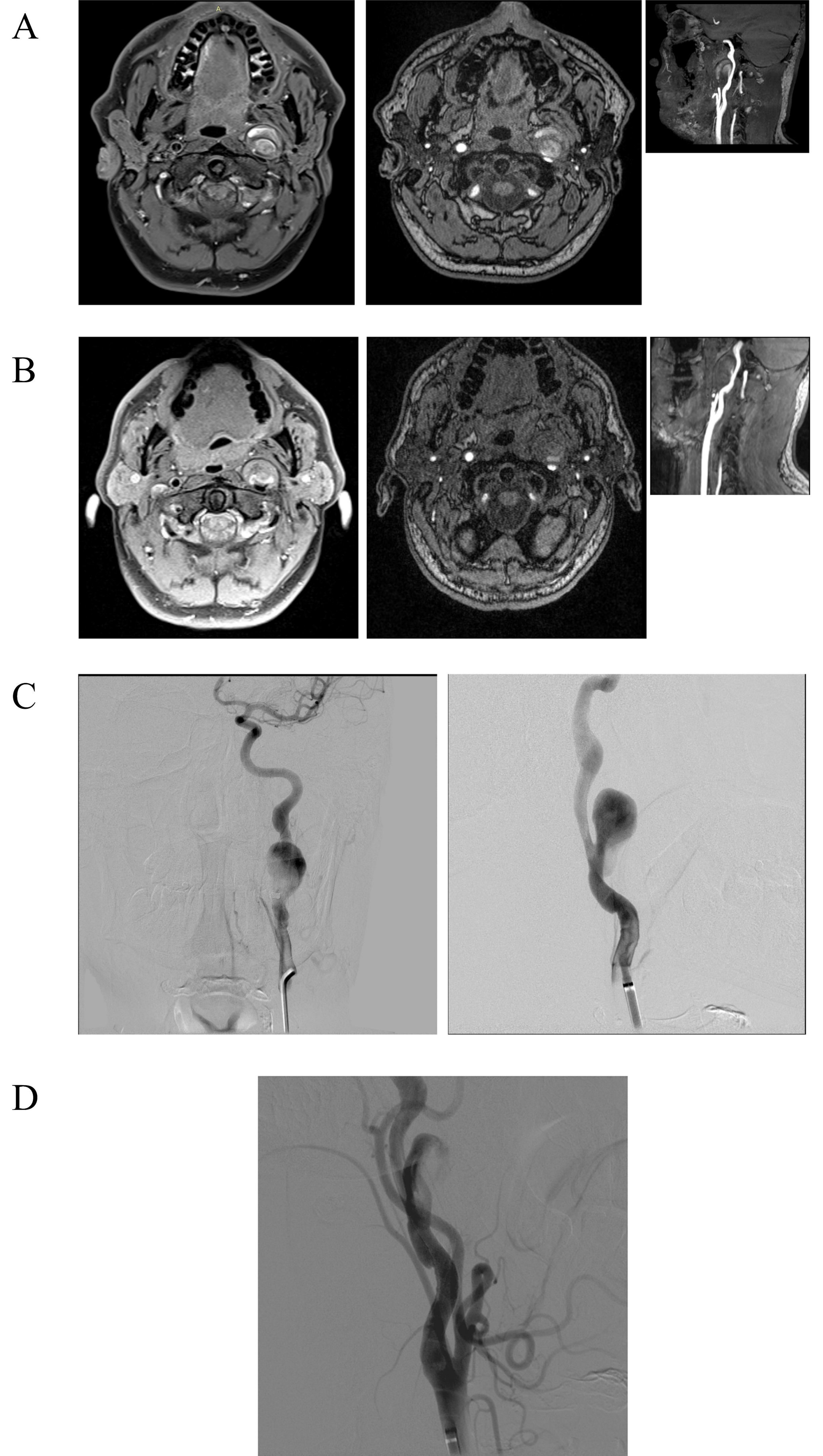


Fig.1

A: T1 MRI and MRA at the baseline

B: T1 MRI and MRA six months later (embolization with acute ischemic stroke)

C: Cerebral Angiography showed the dissecting pseudoaneurysm

D: Cerebral Angiography after endovascular treatment with Flow-diverter device

- Debetto S, Leys D. Cervical-artery dissections: predisposing factors, diagnosis, and outcome. *Lancet Neurol.* 2009 Jul;8(7):668-78.

- Daou B, Hammer C, Chalouhi N et al; Dissecting pseudoaneurysms: predictors of symptom occurrence, enlargement, clinical outcome, and treatment. *J Neurosurg.* 2016 Jan 29:1-7.

- Engelter ST, Traenka C, Von Hessling A; Diagnosis and treatment of cervical artery dissection. *Neurol Clin.* 2015 May;33(2):421-41.