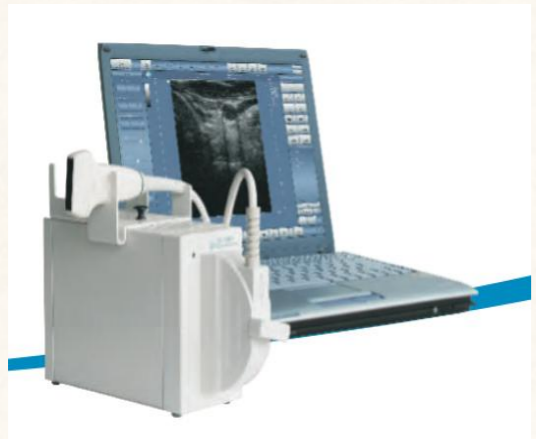



# DIAPHRAGMATIC FUNCTION EVALUATION BY NEUROMUSCULAR ULTRASOUND IN AMYOTROPHIC LATERAL SCLEROSIS.

Sartucci F. <sup>1,2,3</sup>, Bocci T. <sup>1,2</sup>, Del Gamba C. <sup>1,2</sup>, Di Rollo A. <sup>2</sup>, Barloscio D. <sup>1,2</sup>, Parenti L. <sup>1,2</sup>, Santin M. <sup>2</sup>, Rossi B. <sup>4</sup>, Dolciotti C. <sup>4</sup>, Cavalli L. <sup>4</sup>, Pelagatti A. <sup>4</sup>, Bongioanni P. <sup>4</sup>,



<sup>1</sup> Dipartimento di Medicina Clinica e Sperimentale, Unità di Neurofisiopatologia, Università di Pisa, Pisa;  
<sup>2</sup> DAI Specialità Mediche, Azienda Ospedaliero-Universitaria Pisana (AOUP), Pisa;  
<sup>3</sup> Istituto di Neuroscienze, CNR, Pisa.  
<sup>4</sup> U.O. Neuroriabilitazione, Azienda Ospedaliero-Universitaria Pisana (AOUP), Pisa.

**Introduction and aims:** Amyotrophic Lateral Sclerosis (ALS) is characterized by progressive weakness of all muscle groups, and in most cases death is due to ventilatory failure caused by respiratory muscle weakness (Kaplan and Hollander, 1994). Moreover respiratory failure represents an unavoidable step in patients (pt.) with ALS and monitoring respiratory muscle weakness is important. Traditionally diaphragmatic function has been tested and monitored using neurophysiology tests: diaphragm Compound Muscle Action Potentials (CMAP), phrenic Nerve Conduction (NCS) and diaphragm Electromyography (EMG) (Pinto et al, 2009, de Carvalho, 2004). The development of diaphragm ultrasound (US) (Cartwright, 2011; Hobson-webb, 2012; Walker, 2015) may provide a useful tool to supplement clinical, functional and neurophysiological assessment of respiratory muscle weakness (Sarwal et al, 2013; Roriz et al, 2015; Simon and Kirnam, 2016). Our aim was to evaluate sonographic changes (thickness and echogenicity) in the costal portion of the diaphragm at rest and during inspiration and expiration and size of phrenic nerve (CSA); data were correlated with test of respiratory function and disease severity in an attempt to stage respiratory impairment avoiding pt. risk and discomfort.

**Materials and Methods:** 11 consecutive SLA pt. (9 m e 2 f, mean age: 63.9 ± 9.5 yrs), followed at the Neurorehabilitation Unit of our Hospital, were assessed. Inclusion criteria were: diagnosis of ALS definite or probable ("El Escorial-Revised criteria" and "Awaji electrodiagnostic algorithm": Brooks et al., 2000; de Carvalho et al., 2008), disease duration > 2 yrs, age > 18 yrs, ability to perform spirometry. Exclusion criteria: pregnancy, diabetes, respiratory disease, dementia, non-invasive ventilation (NIV), tracheostomy. As controls, we used a group of 24 healthy volunteer subjects homogeneous for age and gender with patients, recruited among the Unit's staff.

In all were performed:

**Spirometry evaluation:** CV, FVC, FEV<sub>1</sub>;

**Hemogas analyses:** BO<sub>2</sub>, BCO<sub>2</sub>, pH, HCO<sub>3</sub>.

**Neuromuscular Ultrasound:** all investigations were performed using a Telemed Echo-wave II device in conventional B-Mode with pt. sitting on wheelchair or lying on the cot. Diaphragm thickness and dynamic changes with the breath were measured.

**Thickness:** on anterior axillary, between VII and IX intercostal spaces, with patients in supine position (Pinto et al., 2016). The measurement should be made at the zone of apposition, inferiorly to the costophrenic angle, where the diaphragm contacts the inner aspect of the chest wall (Fig. 1). Thickness measurement should be performed with visualization of both the pleural and peritoneal membranes with an angle of incidence of the ultrasound beam close to 90 degrees. It is important to define the intercostal space where the thickness of the diaphragm is measured as it varies, with the more inferior portions of the diaphragm being thicker than more upper portions. It has been established that 0.2 cm is the cut-off below which diaphragm atrophy is defined.

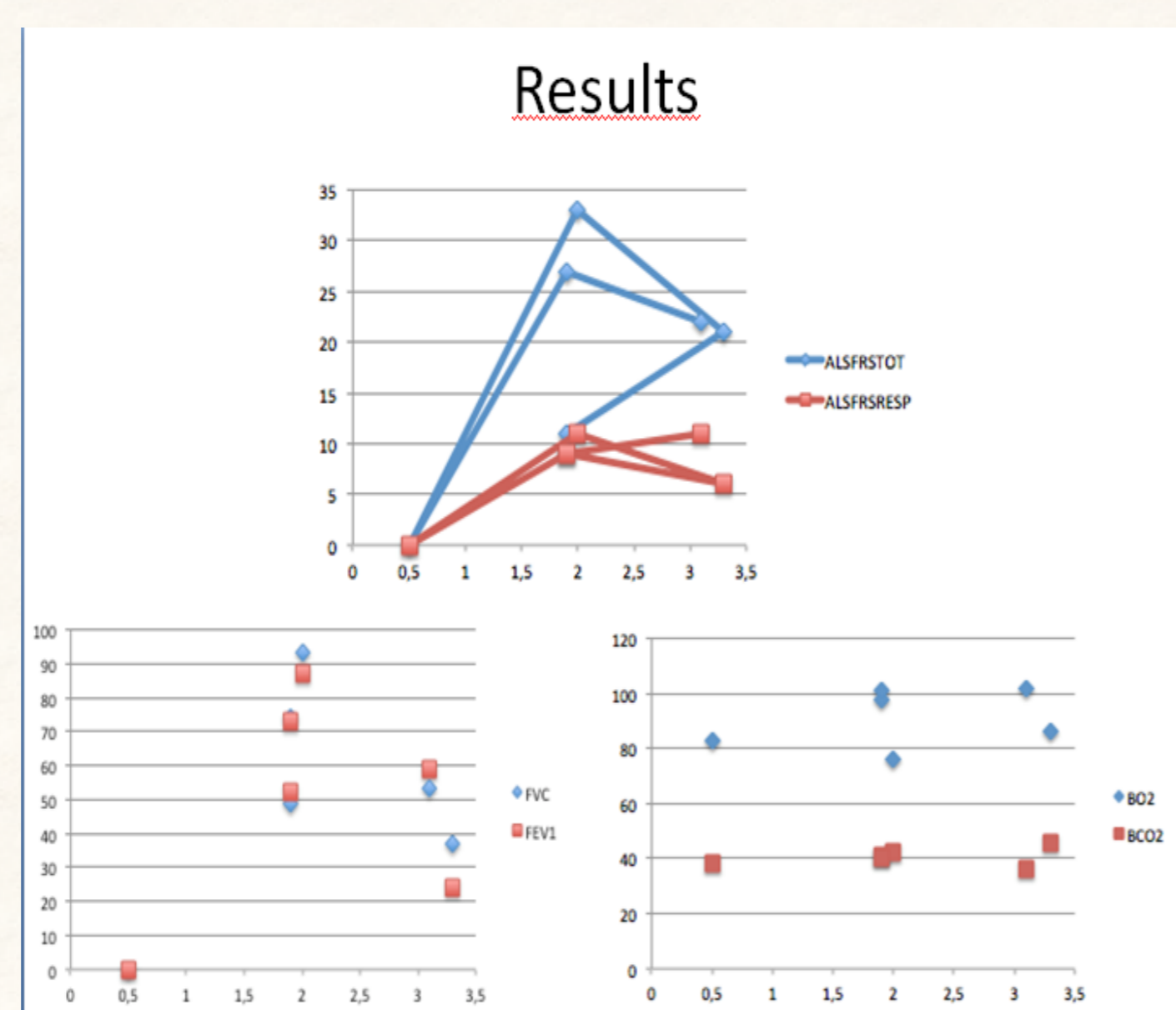


Fig. 3. Relationship between ALS Functional Rating Scale (ALSFRS, either total or respiratory.), spirometry evaluation CV, FVC, FEV<sub>1</sub> and Hemogas analyses BO<sub>2</sub>, BCO<sub>2</sub>, pH HCO<sub>3</sub>.

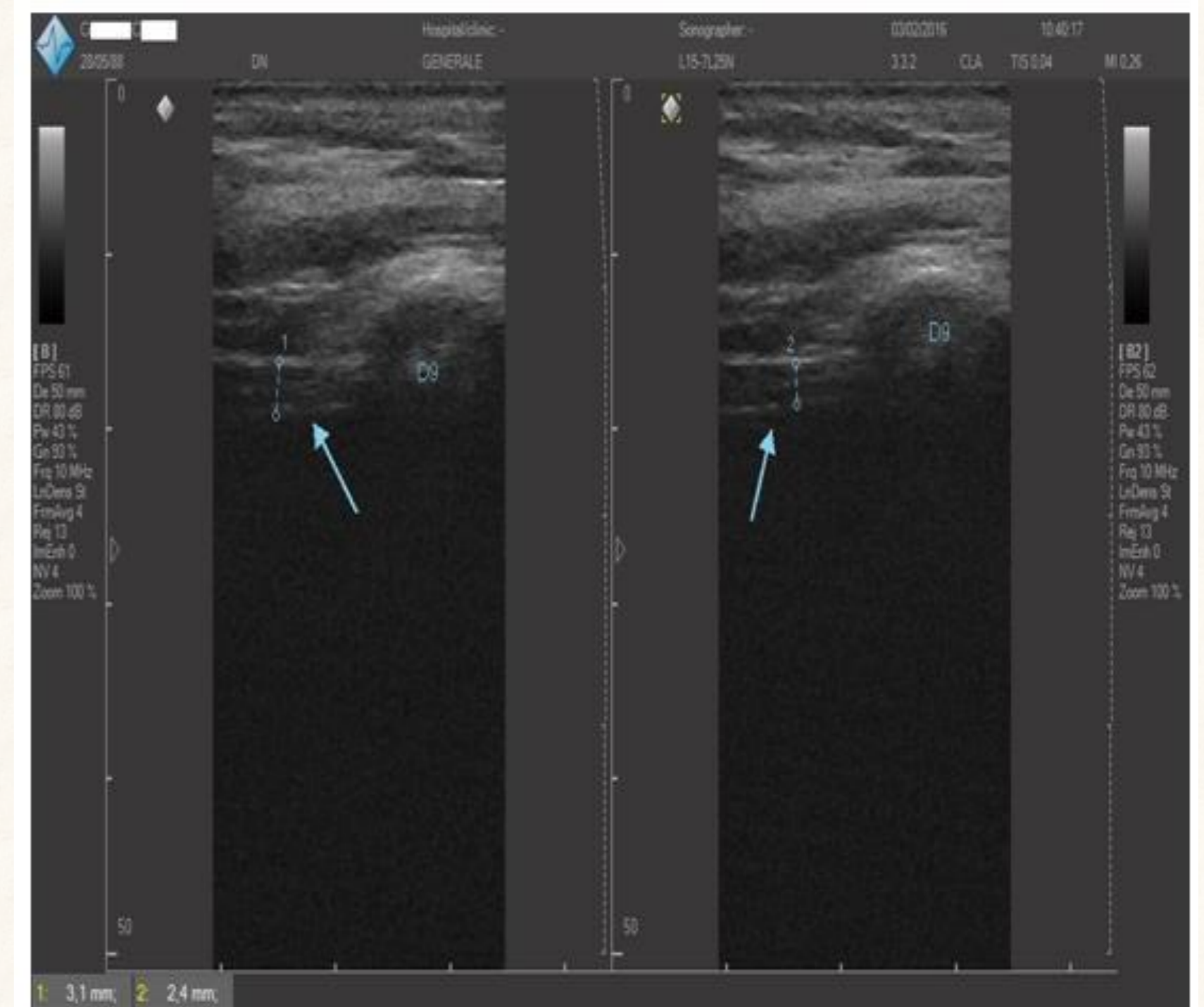


Fig. 1. exemplificative pattern of diaphragm ultrasound thickness changes at the point of full inspiration and expiration in a normal subject: note as the normal diaphragm (arrow) is seen between the ribs (C9), and deep to the abdominal and intercostal muscles during exhalation (right side) and is thicker during maximal inhalation (left side).

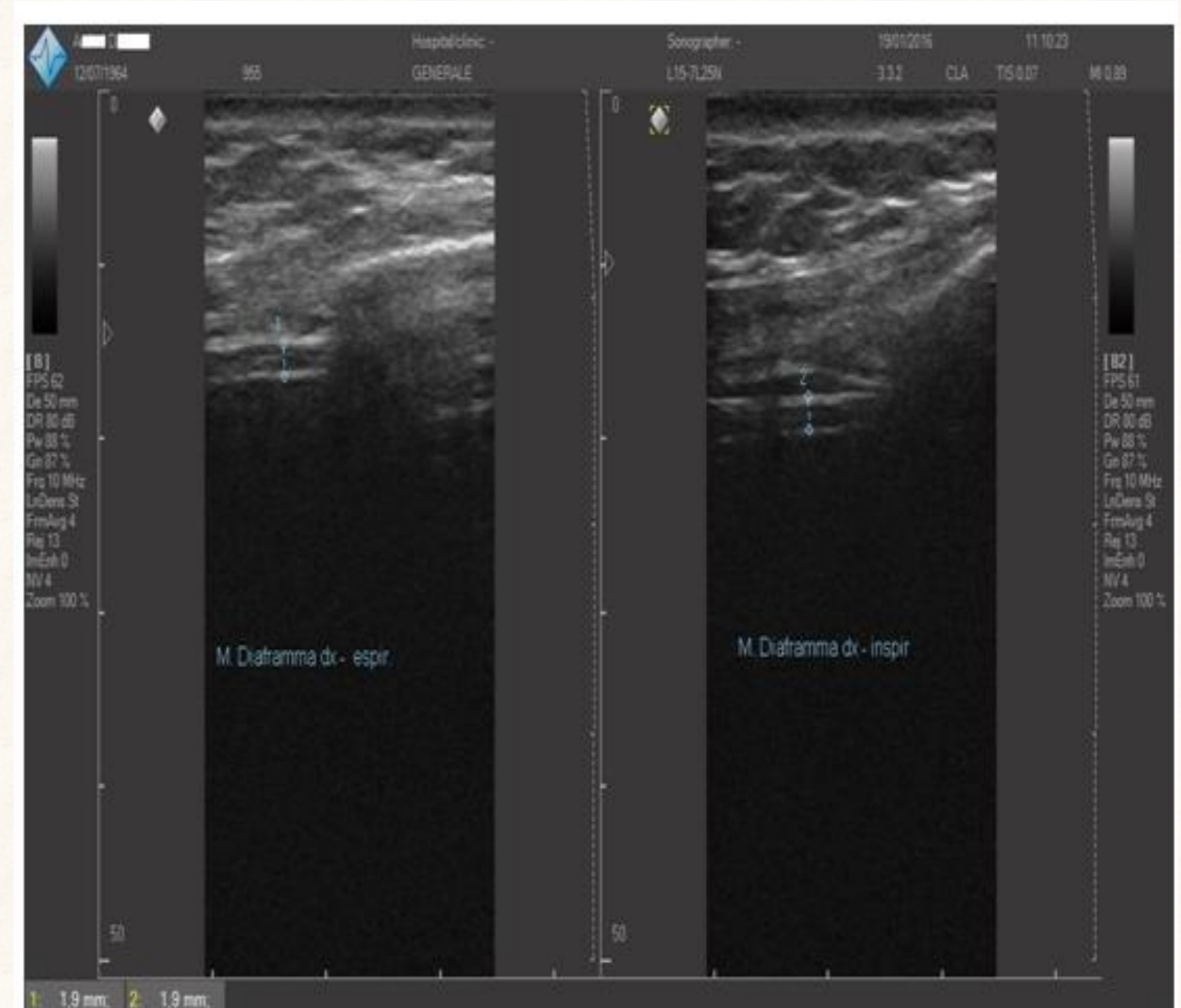


Fig. 2. diaphragm ultrasound thickness changes at the point of full inspiration and expiration in a patient with ALS and respiratory insufficiency: note the lack of diaphragm (arrow) thickens on inspiration (right side, severe pattern).

**Results:** Mean rest thickness was reduced in all cases (2.18 vs 3.45 mm); changes in thickness during inspiration and expiration were also reduced (0.4 vs 1.16 mm) and loss in the most severe cases (3 pt.) (Fig. 2). In some pt. fasciculation potentials were detected; never fibrillation. Diaphragm size did not correlated correlated with disease severity or respiratory tests (Fig. 3).

**Discussion:** The degree of respiratory involvement is an important prognostic factor and determines when to apply "Non-invasive ventilation" (NIV) (Andersen et al, 2007; Miller et al, 2009). There is no single test that can predict the presence of hypoventilation. Usually "Respiratory muscle strength" (RMS) is studied by:

1) **Spirometry**, that have some limitations: cognitive decline, reduced motivation, weakness orofacial muscles, abnormalities in the upper airways (Lyall et al, 2001; Fregonezi et al, 2013).

2) **Needle Electromyography of diaphragm muscle:** exhibit the following limitations: technically demanding, moderately invasive, it shows large inter-individual differences (Cruz Martinez et al, 2000).

Diaphragm ultrasound instead resulted a simple, fast and easy method, painless and risk-free, devoid of EMG complication particularly pneumothorax, able to provide useful functional and structural insight to better understand or monitoring diaphragm role and the degree of respiratory failure in ALS pt. It provides both structural and functional informations, useful for understanding the role of diaphragm muscle in ALS patient respiratory dysfunction. Furthermore may predict the incoming respiratory failure, allowing to undertake promptly appropriate therapeutic measures. Moreover is desirable that US become an indispensable component of the diagnostic armamentarium of the neuromuscular physician.