

## BACKGROUND

Myocardial dysfunction is part of the natural history and the most frequent cause of death in Duchenne muscular dystrophy (DMD). Timing of onset, progression and severity can vary. Standard echocardiography has known limitations in DMD patients since left ventricular (LV) abnormalities are often subclinical and detectable by standard echocardiography only in the advanced stage of the disease. Recently an expanded use of cardiac magnetic resonance imaging (CMR) or new echocardiographic imaging techniques, including myocardial strain analysis, has been suggested (McNally et al. 2015). Moreover, there is increasing evidence that cardioprotective drugs, like ace-inhibitors and angiotensin receptors blockers, are able to delay the progression of myocardial damage. Prevention strategies are always based on prompt identification of the earliest stages of disease progression. Furthermore, the ongoing clinical trials, investigating the effect of exon skipping, stop codon suppression and antifibrotics in DMD, target at younger ambulatory DMD patients. It is therefore mandatory to validate new tools able to monitor cardiac function in the earliest phase of cardiac involvement to detect concomitant benefits or toxicity, to better characterize the natural history and to test the correlation between cardiac and functional profile in the younger population. Scanty literature is present on the use of myocardial echo-strain analysis speckle tracking echocardiography in DMD (Ryan et al. 2013).

## AIM

The aim of this study was to test the hypothesis that the two-dimensional (2D) strain with speckle tracking technique might detect early LV changes not detected by standard echo and the assess the correlation between 2D strain values and age and functional performances, measured by 6 minute walk test (6MWT) and North Star Ambulatory Assessment (NSAA) in the ambulatory phase of the disease.

## MATERIALS AND METHODS

We enrolled DMD patients consecutively seen in our Institution with confirmed genetic diagnosis and normal standard echo (ejection fraction (EF) >55%) at conventional echocardiographic examination. Cardiovascular assessment was based on clinical evaluation, physical examination, 12-leads electrocardiogram and echocardiography, particularly aimed to study myocardial mechanics. A conventional 2D-echocardiogram was performed with an Echopac (GE, Vivid 7). Left ventricular diameters, wall thickness, fractional shortening and mass were calculated. Diastolic function was studied by mitral early inflow Doppler velocity (E wave), early to late (A wave) inflow Doppler velocity ratio (E/A), medial and lateral mitral annular tissue Doppler imaging (TDI) early inflow velocity (E') and the E/E' ratio. Care was taken to obtain clear loops of the LV in apical 4-chamber (Ap4-ch), 2-chamber (Ap2-ch) and 3-chamber (Ap3-ch) views, and also parasternal short axis views at the level of mitral valve (MV-Sax), papillary muscles (PM-Sax) and apex (AP-Sax). All measures and functional evaluations were processed off-line on the Echopac GE, Vivid 7 workstation. Systolic function was expressed as global LV function (ejection fraction, EF), longitudinal systolic function by M-Mode echocardiography and TDI, longitudinal and circumferential strain by speckle tracking echocardiography (STE). Ejection fraction was obtained with biplane Simpson's method. Longitudinal systolic function was assessed by mitral and tricuspid annular plane systolic excursion by M-mode echocardiography (MAPSE, TAPSE), and by TDI mitral annular systolic velocity (S'). Furthermore, systolic longitudinal LV deformation was studied by STE, recording both global and segmental strain values, expressed as percentage. Also, global and segmental circumferential deformation was studied at basal, medial and apical LV level. Neuromuscular assessment included the North Star Ambulatory Assessment (NSAA) and the 6-minute-walk test. (6MWT) evaluation in ambulant patients.

## RESULTS

- We included **33** patients with DMD with normal standard echo (age range: 5-15 yrs, mean 10.2 yrs  $\pm$  3.6 SD) and **20** age-matched healthy controls. One patient was excluded from the analysis due to poor quality echocardiographic images. The cohort was divided in **Group 1** aged under 9 years (n=16) and **Group 2** over this age (n=16).
- Conventional parameters, diameters, wall thickness, LV volumes were similar between patient groups and healthy children. Although EF was within the normal range, a significant reduction was seen in Group 2 and the same occurred for FS and early inflow (E') velocity. Longitudinal function explored by conventional parameters like MAPSE, TAPSE and S' was significantly reduced even in younger patients and the same behavior was noted for E velocity and Isovolumic relaxation time (IVRT) (Table 1).
- **Myocardial deformation analysis.** Global longitudinal strain (GLS) was significantly reduced in patients vs controls. Furthermore, GLS was lower in older vs younger patients (Figure 1 and Table 2). Conversely, global circumferential strain (GCS) was reduced in older patients but not in younger patients vs controls, with a significant difference between Group 1 and 2 (Figure 1 and Table 2).
- **NSAA and the 6MWT** evaluation were successfully performed in 24 (age range: 5-11 yrs, mean: 9.2 yrs  $\pm$  2.6 SD) out of 32 patients. Four patients were not compliant and four were not ambulant. In the ambulant group we found a significant positive correlation between GLS and the 6MWT ( $r = 0.38$ ,  $p < 0.05$ ).

	Controls vs Group 1	Controls vs Group 2	Group 1 vs Group 2
FS%	,217	,000	,013
EF% BP Simpson	,285	,000	,001
MAPSE medial	,002	,041	,387
TAPSE	,008	,000	,006
E	,000	,000	,893
E'	,134	,000	,034
S'	,001	,004	,949
IVRT	,013	,012	,863

Table 1: p value level for Mann-Whitney test: Abbreviations: FS fractional shortening, EF ejection fraction, MAPSE mitral annular plane systolic excursion, TAPSE tricuspid annular plane systolic excursion, E early mitral inflow velocity, E' early diastolic mitral annular velocity, S' systolic mitral annular velocity, IVRT iso-volumic relaxation time.

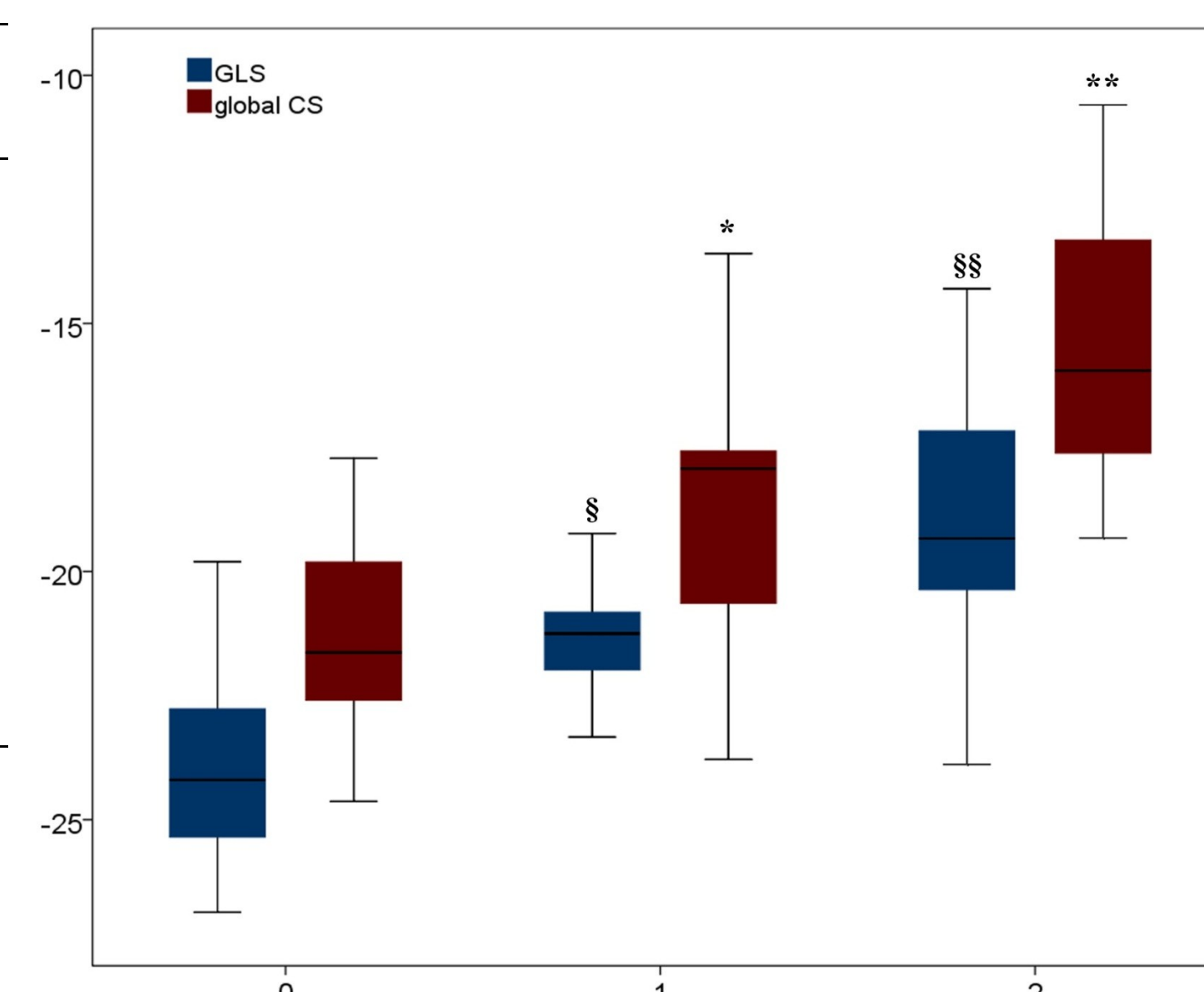
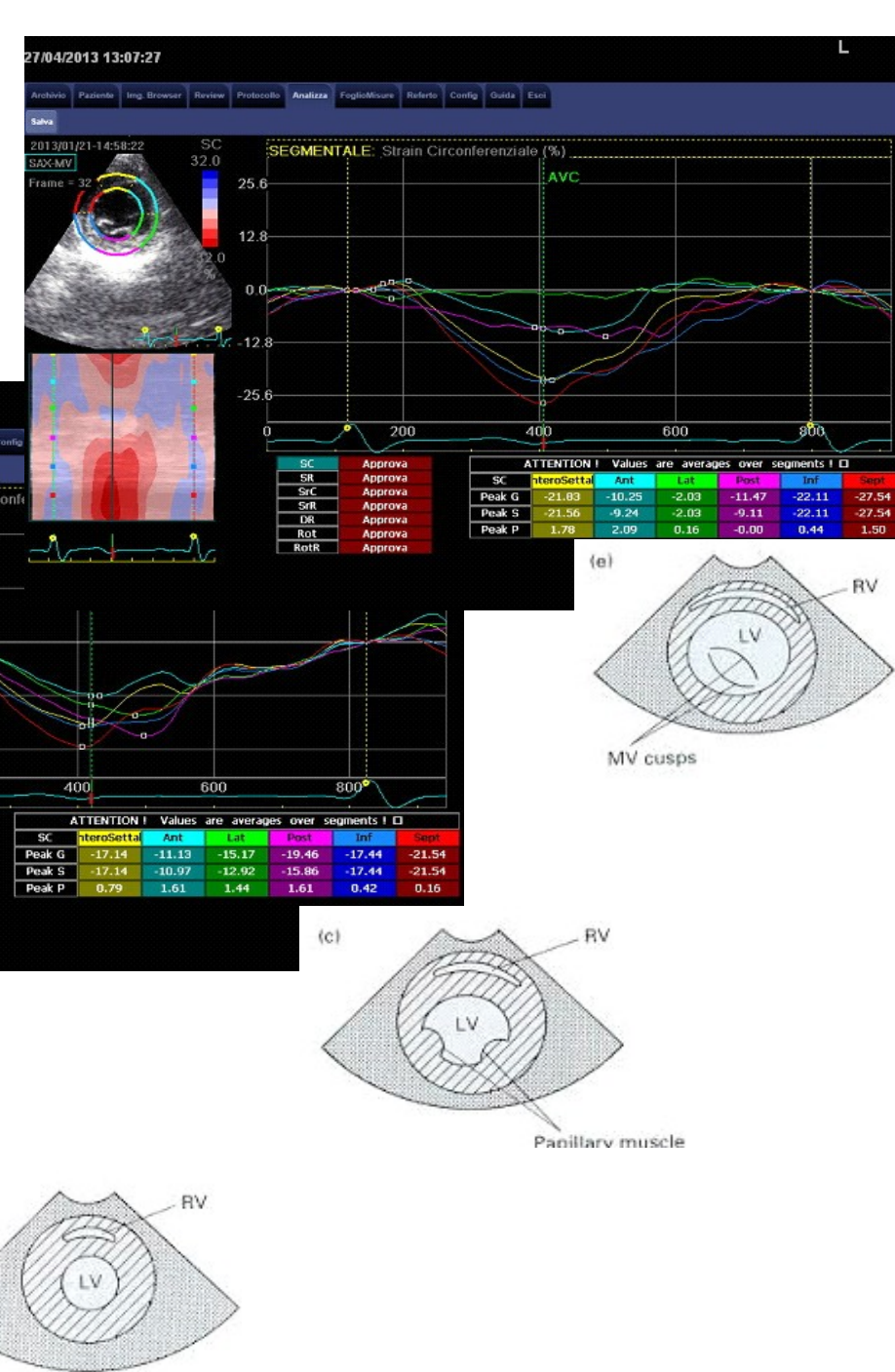


Figure 1: Box and whiskers plots for GLS (blue bars) and GCS (red bars) in controls (group 0), younger DMD (group 1) and older DMD (group 2). Solid horizontal lines = median values; error bars = 95% confidence intervals; shaded area = Interquartile range. Comparisons were carried out among the groups, by Mann-Whitney test; significance levels: §  $p < 0.020$  vs controls; §§  $p < 0.05$  vs group 1 and  $p < 0.005$  vs controls (GLS); \*  $p = ns$  vs controls; \*\*  $p = 0.026$  vs group 1 and  $p = 0.003$  vs controls (GCS).

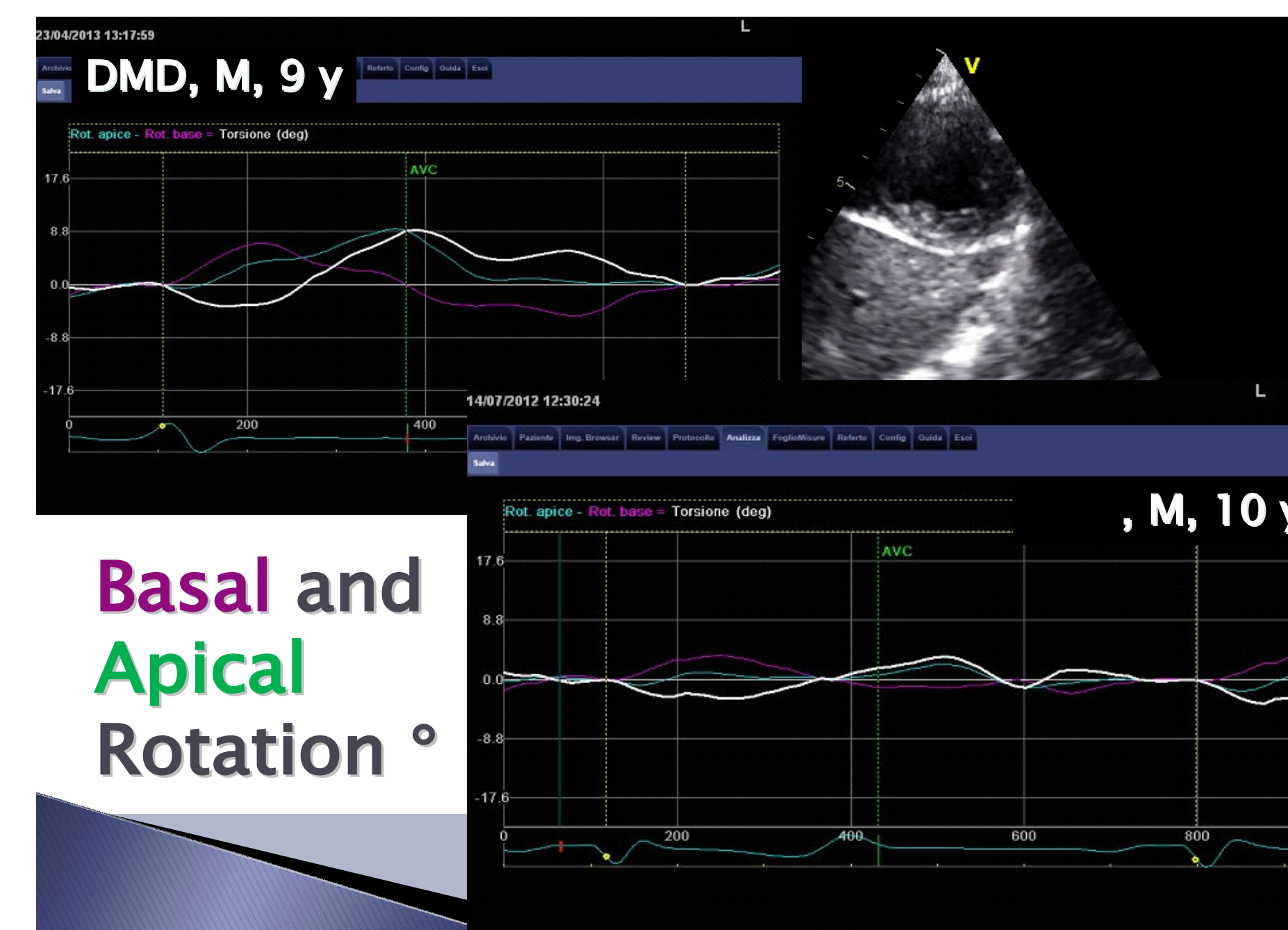
	Controls vs Group 1	Controls vs Group 2	Group 1 vs Group 2
3ch GLS	,059	,000	,004
4ch GLS	,026	,001	,138
2ch GLS	,087	,005	,033
GLS	,020	,001	,005
MV GCS	,142	,000	,026
PM GCS	,065	,000	,539
AP GCS	,603	,007	,050
GCS	,186	,003	,026

Table 2: p value level for Mann-Whitney test: Abbreviations: 3ch 3-chamber view, GLS global longitudinal strain, 4ch 4-chamber view, 2ch 2-chamber view, MV mitral valve level, SAX short-axis view, GCS global circumferential strain, PM papillary muscles level, AP apical level.

## Circumferential Strain %



DMD, M, 8 y



Basal and Apical Rotation °

## CONCLUSIONS

The main findings of this study are:

- The impairment of both GLS and GCS is detectable by means of speckle tracking echocardiography (STE) in asymptomatic DMD patients with traditional parameters of systolic and diastolic function within the normal range.
- The reduction of both GLS and GCS showed a progressive trend, with a worsening of cardiac mechanics with age.
- While GLS was altered already in younger subjects, the reduction of GCS compared to control subjects was significant only for the group of patients older than 9 years

Regarding the motor functional data, we found a significant correlation between 6MWT and GLS, however further studies on larger cohort are warranted to draw meaningful conclusions.

Further longitudinal studies are needed to establish the validity of this method as strategy for early detection of myocardial involvement for an effective preventive therapeutic management and as an additional outcome measures to test the efficacy on heart of new therapeutic approaches.

## REFERENCES

- McNally EM1, Kaltman JR1, Benson DW2, Canter CE2, Cripe LH2, Duan D2, Finder JD2, Groh WJ, Hoffman EP2, Judge DP2, Kertesz N2, Kinnett K2, Kirsch R2, Metzger JM2, Pearson GD2, Rafael-Fortney JA2, Raman SV2, Spurney CF2, Targum SL2, Wagner KR2, Markham LW1; Working Group of the National Heart, Lung, and Blood Institute; Parent Project Muscular Dystrophy. Contemporary cardiac issues in Duchenne muscular dystrophy. Working Group of the National Heart, Lung, and Blood Institute in collaboration with Parent Project Muscular Dystrophy. Circulation. 2015 May 5;131(18):1590-8.

Ryan TD, Taylor MD, Mazur W, Cripe LH, Pratt J, King EC, Lao K, Grenier MA, Jefferies JL, Benson DW, Hor KN. Abnormal circumferential strain is present in young Duchenne muscular dystrophy patients. Pediatr Cardiol. 2013 Jun;34(5):1159-65. doi: 10.1007/s00246-012-0622-z. Epub 2013 Jan 29.